

Normal Pressure Hydrocephalus

Welcome to **Neuroscience Pearls**: A publication from the UW Medicine Neurosciences Institute. In this issue we bring you key points on recognition, diagnosis, work-up and treatment of normal pressure hydrocephalus (NPH). Recognizing the signs and symptoms of NPH is important as it is currently the only dementia that can be treated.

*Anthony M. Avellino, M.D., M.B.A., Professor, Neurological Surgery; Director, UW Medicine Neurosciences Institute,
Bruce Ransom M.D., Ph.D., Magnuson Professor & Chair, Neurology; Adjunct, Physiology & Biophysics and
Shu-Ching (Gene) Hu, M.D., Ph.D., Assistant Professor of Neurology*

WHAT IS NORMAL PRESSURE HYDROCEPHALUS: NPH is chronic dilatation of the cerebral ventricles with a normal pressure of cerebrospinal fluid (CSF) when measured. It is a type of communicative hydrocephalus. NPH can be idiopathic, or be secondary due to previous subarachnoid hemorrhage, meningitis or head trauma. An estimated 0.4% of the population over 65 has idiopathic NPH. The classic triad of neurological symptoms caused by NPH are gait impairment, dementia and urinary incontinence.

DIAGNOSIS: The diagnosis NPH should be considered when an elderly patient develops the classic triad of symptoms and the neuroimaging study such as CT or MRI shows enlarged ventricles.

WORK-UP: The gold-standard diagnostic test for NPH is a large-volume lumbar puncture (LP) (30-40 ml of CSF removed) or an indwelling lumbar drain; if the neurological symptoms improve with an LP or drain, the diagnosis of NPH is suggested. With a lumbar drain, patients are observed for three days while the CSF is continuously removed, in contrast to short-term observation after transient removal of CSF with an LP. Therefore, a lumbar drain trial is more accurate than a large-volume LP in diagnosing NPH. A formal neuropsychological and physical therapy gait evaluation as well as a total spine MRI is part of the work-up when planning a trial of lumbar drain.

TREATMENT: The treatment for NPH is a ventriculoperitoneal (VP) shunt. A programmable VP shunt is preferable because it allows for adjusting pressure according to the symptoms and for a gradual change in pressure to prevent complications caused by over-drainage such as subdural blood collections.

CLINICAL PEARLS

1. Approximately 0.4% of the population over 65 has idiopathic NPH. The incidence of NPH is expected to rise with our aging population.
2. The classic clinical triad of NPH are gait impairment, dementia and urinary incontinence. In NPH, gait impairment typically occurs early and is the presenting symptom, whereas dementia and incontinence are late phenomena. Therefore, NPH is unlikely with dementia but no or minimal gait impairment, or if dementia precedes gait impairment by more than a few years.
3. NPH's biggest diagnostic challenge is differentiating it from neurodegenerative disorders. Neurodegenerative disorders can have the same symptoms, and in neurodegenerative disorders the cerebral ventricles may appear enlarged due to volume loss, so-called hydrocephalus ex-vacuo. For example, patients with Alzheimer's disease often develop gait impairment and urinary incontinence as the dementia progresses. Similarly, there are Parkinsonian disorders that cause not only gait impairment but also dementia, such as dementia with Lewy bodies, frontotemporal dementia with Parkinsonism and progressive supranuclear palsy. Therefore, it may not always be possible to distinguish between NPH and neurodegenerative disorders based on clinical presentations and neuroimaging studies. Furthermore, it is possible for a patient to have both NPH and a neurodegenerative disorder at the same time. Vascular dementia is another mimicker of NPH. One should bear in mind too that in the elderly, gait impairment can result from orthopedic problems, and urinary incontinence can result from prostate hypertrophy in men and from age-related stress incontinence in women. All these mimickers and confounding factors should be considered when evaluating a patient with possible NPH.
4. On head CT or MRI, the Evan's ratio is useful to distinguish between NPH and hydrocephalus ex-vacuo (**Figure 1**). It is defined as the ratio of the transverse diameter of the anterior horns of the lateral ventricles to the internal diameter of the skull. An Evan's ratio of 0.4 and above is suggestive of NPH, although this is by no means absolute. The CSF flow study by MRI or by radionuclide cisternography is limited in their sensitivity and specificity in diagnosing NPH. Functional neuroimaging modalities such as PET and SPECT are useful for diagnosing neurodegenerative disorders, but their utility in diagnosing NPH is uncertain.

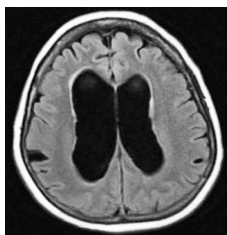


Figure 1: Representative brain MRI of a patient with NPH, A 67-year-old woman developed gait impairment for 1-2 years, followed by urinary incontinence and dementia. Her brain MRI showed marked ventriculomegaly but only slight volume loss and minimal periventricular microvascular disease. Therefore, her ventriculomegaly was out of proportion to volume loss and represented true hydrocephalus rather than hydrocephalus ex-vacuo. Her ventriculomegaly could not be accounted for by cerebrovascular disease either.

5. When the clinical presentation and neuroimaging finding are consistent with NPH, the patient should have the definitive test for NPH, either a large-volume LP or an indwelling lumbar drain. A lumbar drain trial is considered more accurate than a large-volume LP for diagnosing NPH (**Figure 2**).
6. The treatment for NPH is the surgical placement of a VP shunt (**Figure 3**). Different from neurodegenerative disorders, deficits of NPH are potentially reversible if treated timely with a VP shunt. If the diagnosis of NPH is delayed, irreversible disease progression ensues.

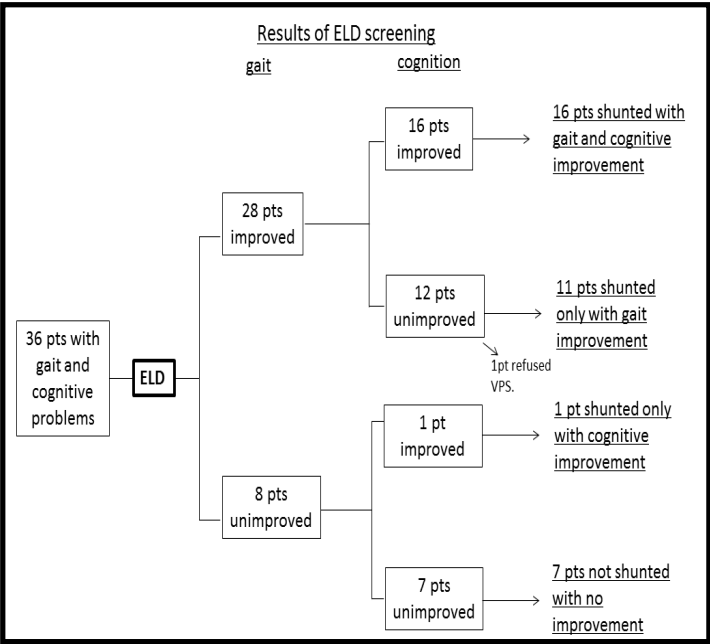


Figure 2: Flowchart showing results of our ELD screening in gait and cognition and assignments of shunting in our recent initial 36 patients. **ELD** = external lumbar drainage; **pts** = patients; **VPS** = ventriculoperitoneal shunting.

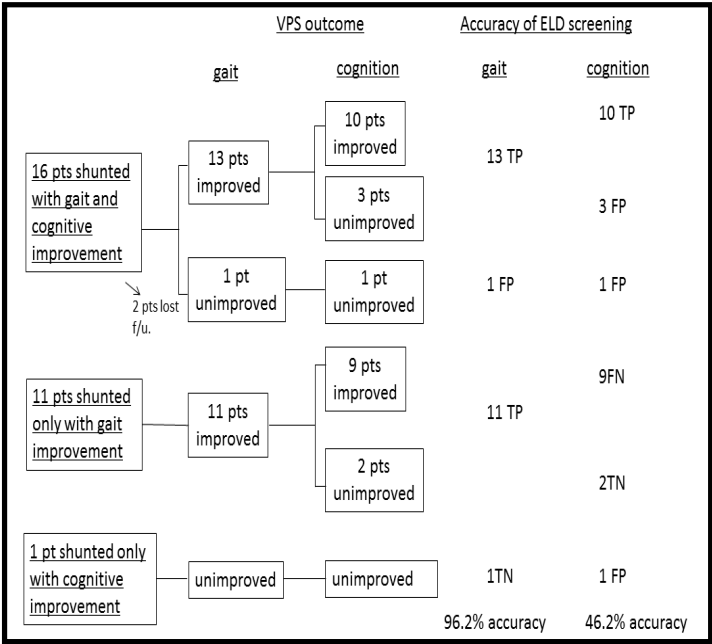


Figure 3: Flowchart showing VPS outcome in gait and cognition and the accuracy of the ELD screening in each symptom of our initial 36 patients. **ELD** = external lumbar drainage; **FN** = false negative; **FP** = false positive; **pts** = patients; **TN** = true negative; **TP** = true positive; **VPS** = ventriculoperitoneal shunting.

ESSENTIAL CITATIONS

- McKhann G, Mayeux R; Brain drain: A bottom-up approach to normal pressure hydrocephalus. *Ann Neurol.* 2010 Oct;68(4):415-7.
- Eide PK, Sorteberg W; Diagnostic intracranial pressure monitoring and surgical management in idiopathic normal pressure hydrocephalus: a 6-year review of 214 patients. . *Neurosurgery.* 2010 Jan;66(1):80-91.
- Hamilton R, et al; Lack of shunt response in suspected idiopathic normal pressure hydrocephalus with Alzheimer disease pathology. *Ann Neurol.* 2010 Oct;68(4):535-40.


Dr. Shu-Ching Hu is Assistant Professor of Neurology at UW Medicine.

Dr. Anthony Avellino is Director of UW Medicine Neurosciences Institute and Professor of Neurological Surgery at UW Medicine.

Both are among a select group of neurologists and neurosurgeons, fellowship-trained to treat complex neurological/neurosurgical problems such as NPH. They are both nationally renowned experts, and co-lead our comprehensive and multidisciplinary NPH clinic.



Dr. Anthony Avellino



Dr. Shu-Ching Hu