

Multi-Institutional Hematopathology Interesting Case Conference

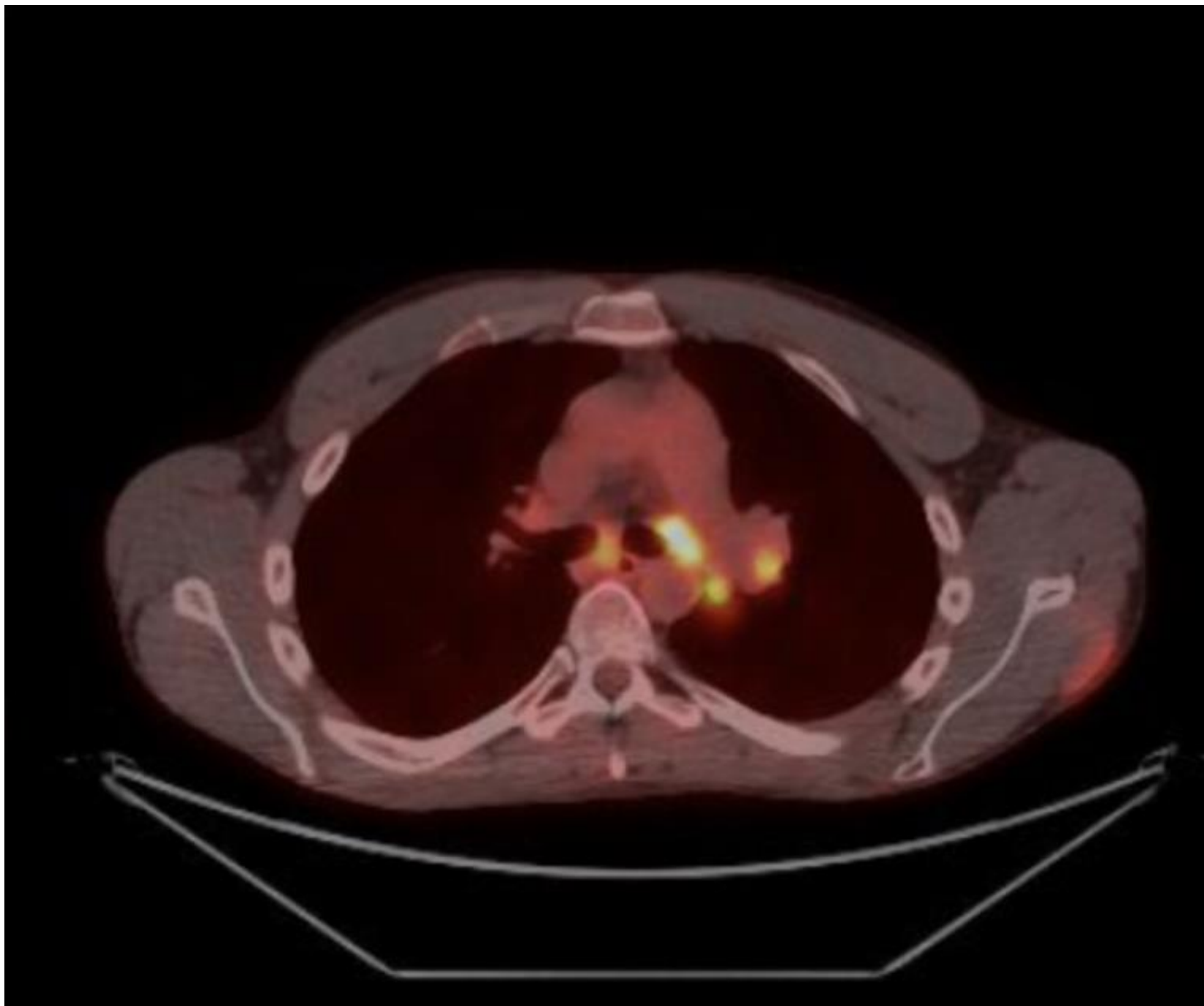
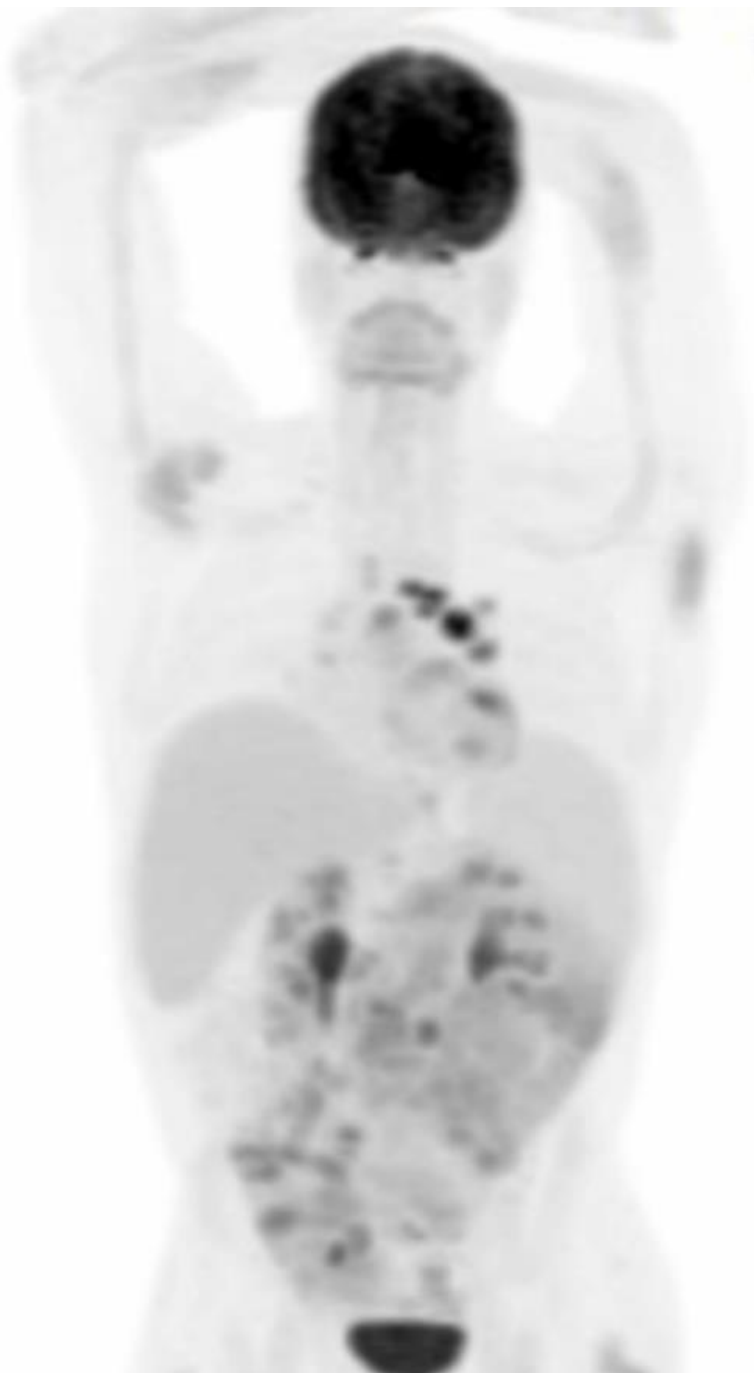
Nicholas Haslett, MD
Hematopathology Fellow
Memorial Sloan Kettering Cancer Center
New York, NY

Financial disclosures / Conflicts of Interest

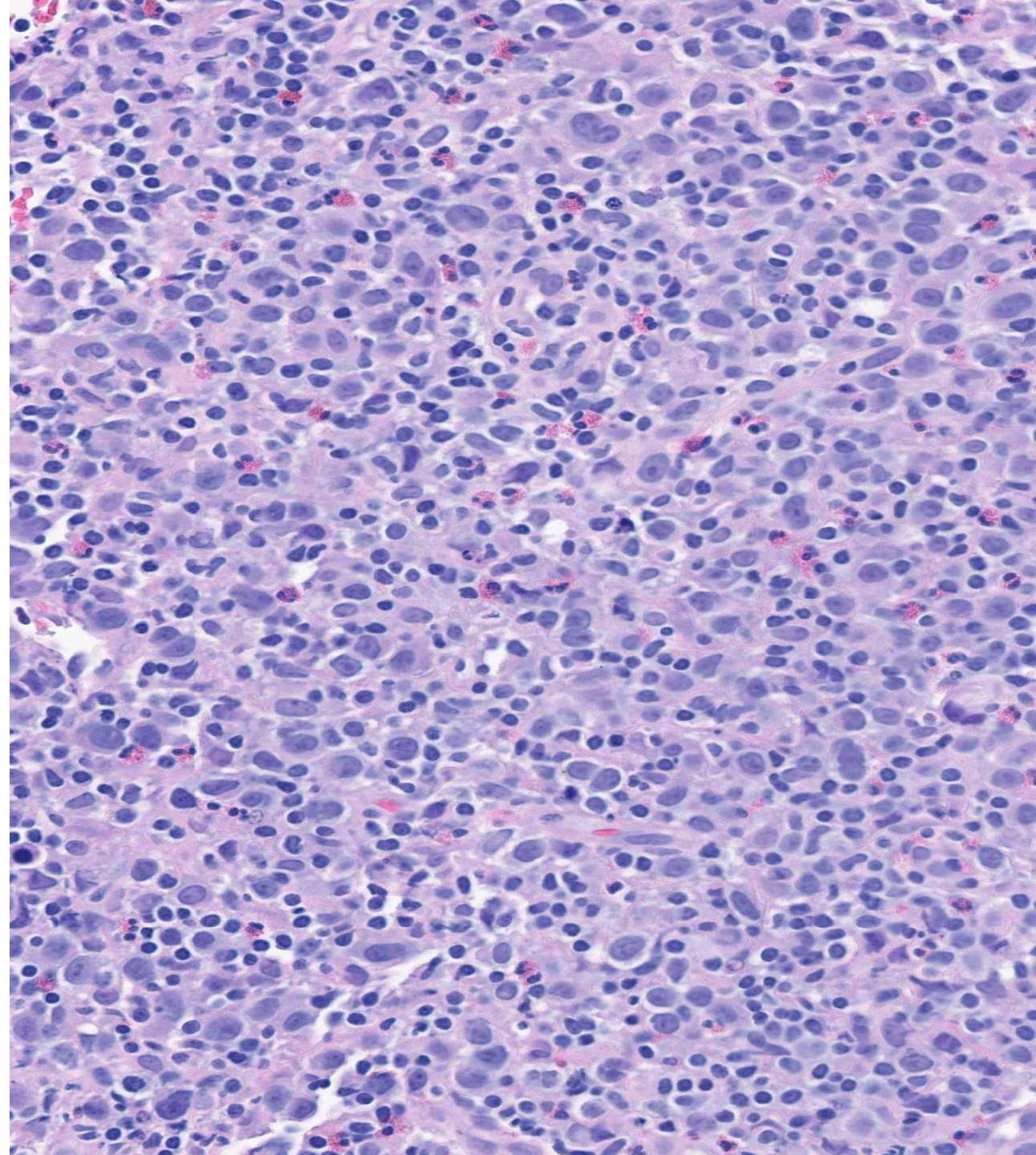
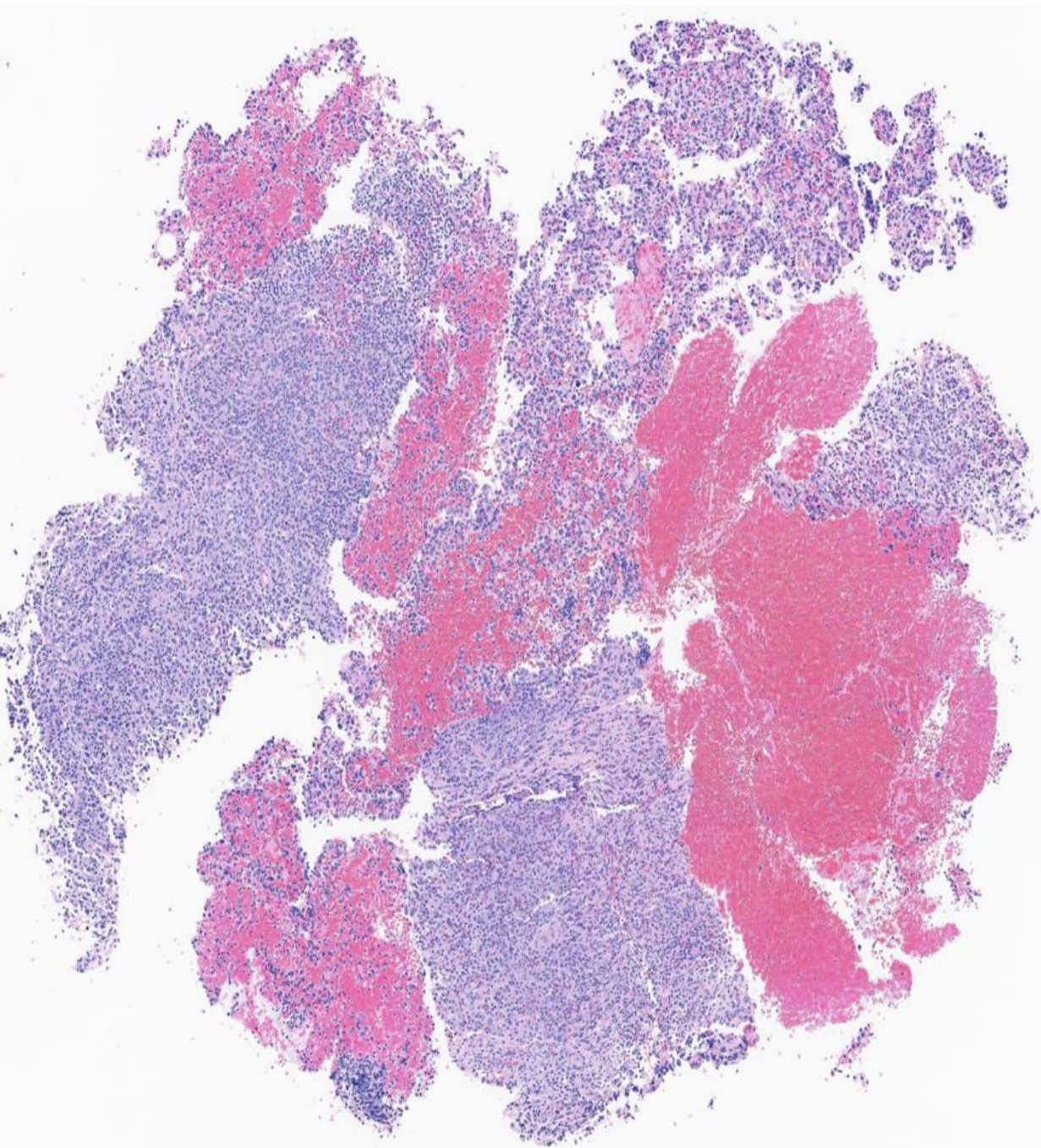
- Nothing to disclose

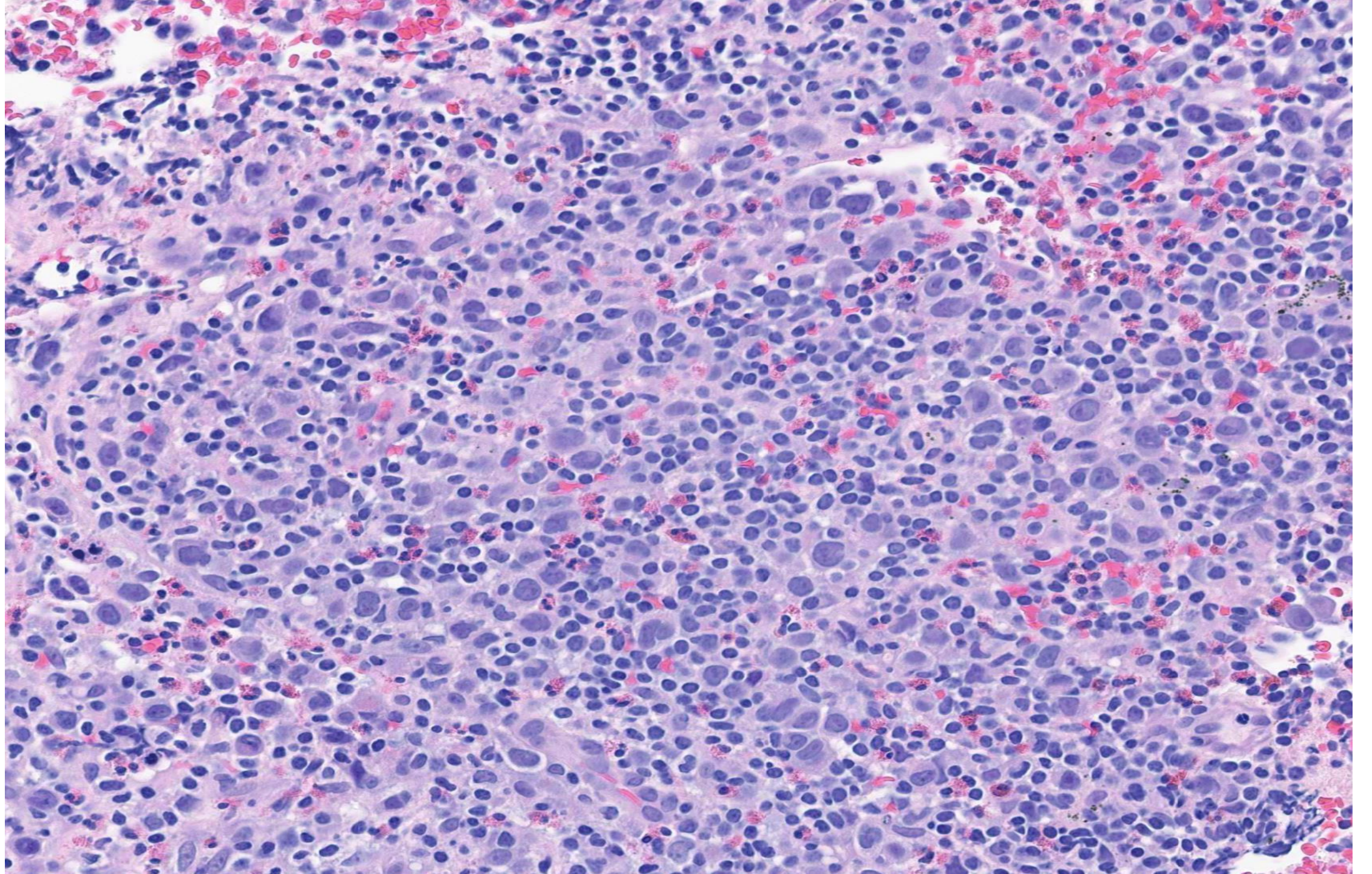
31M

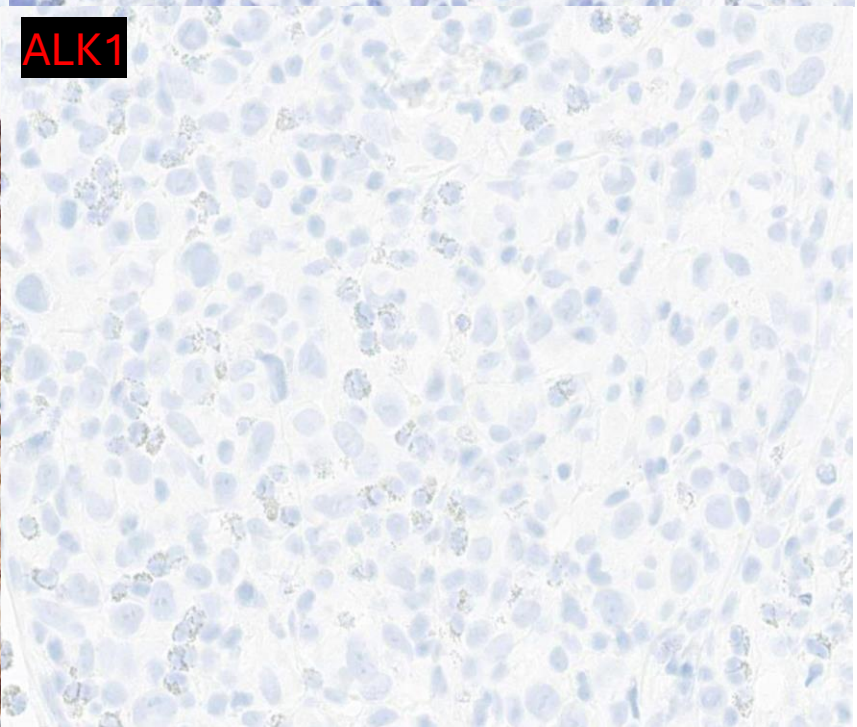
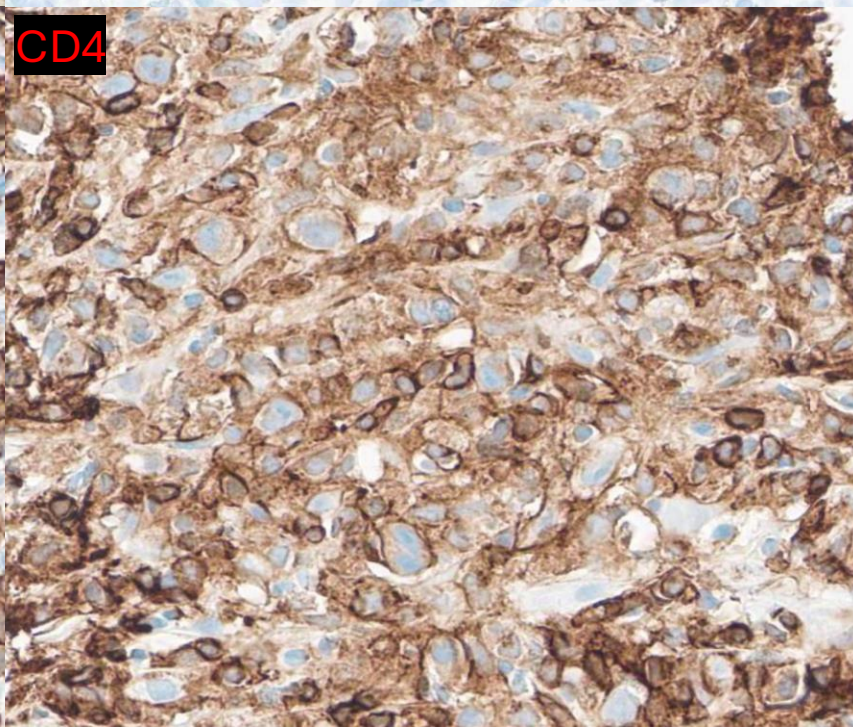
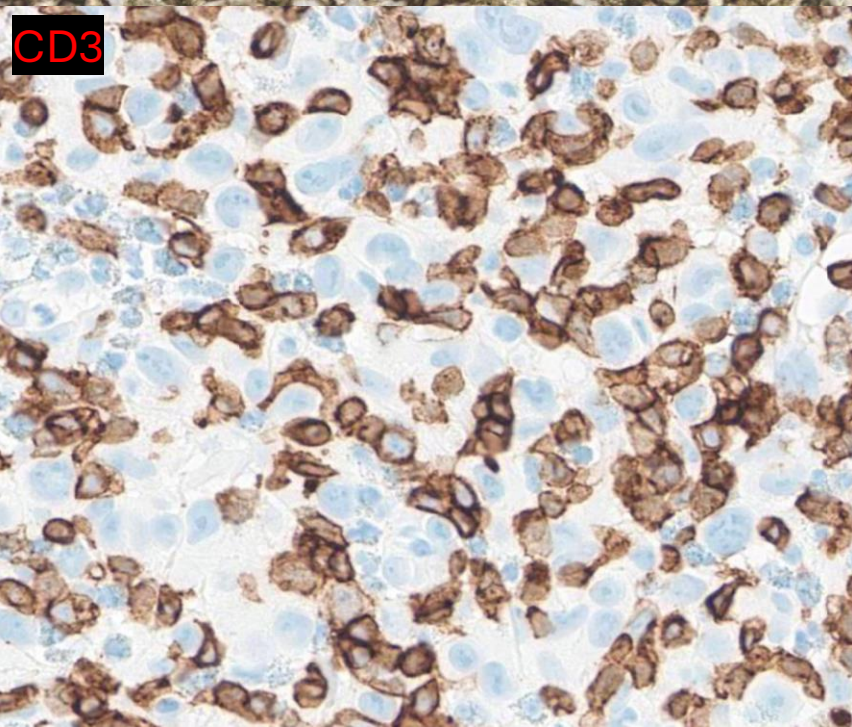
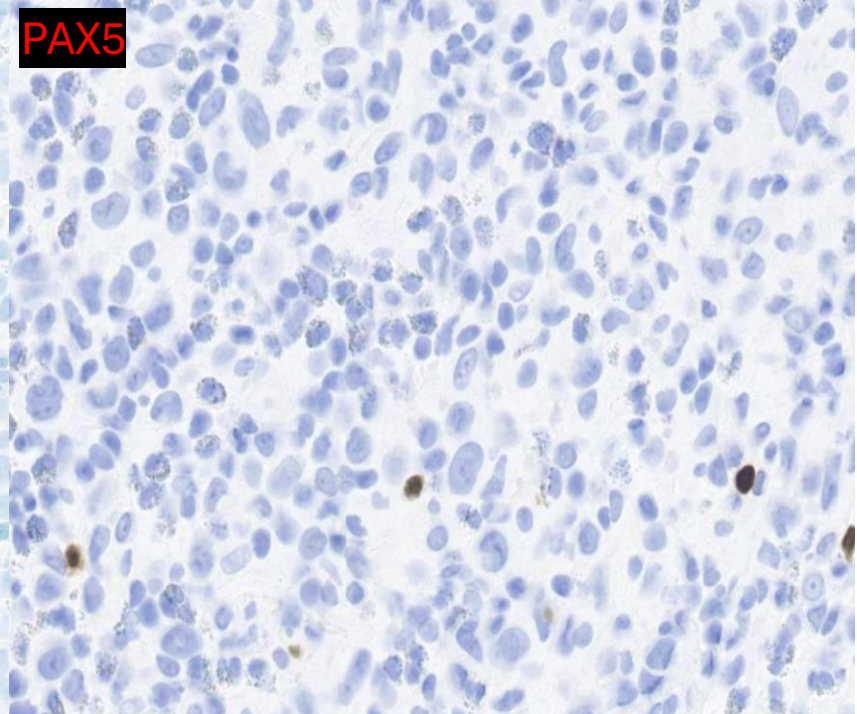
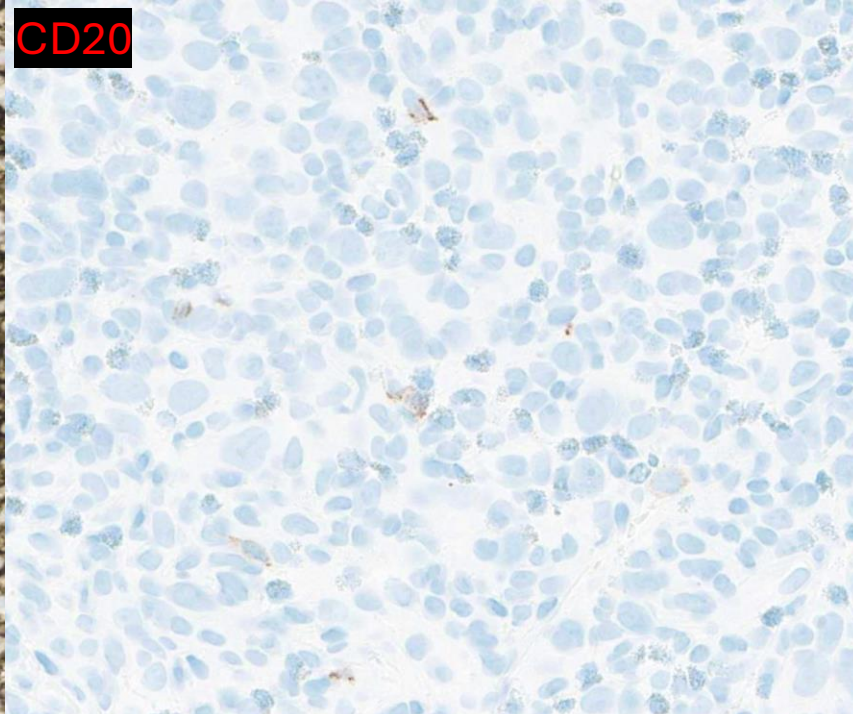
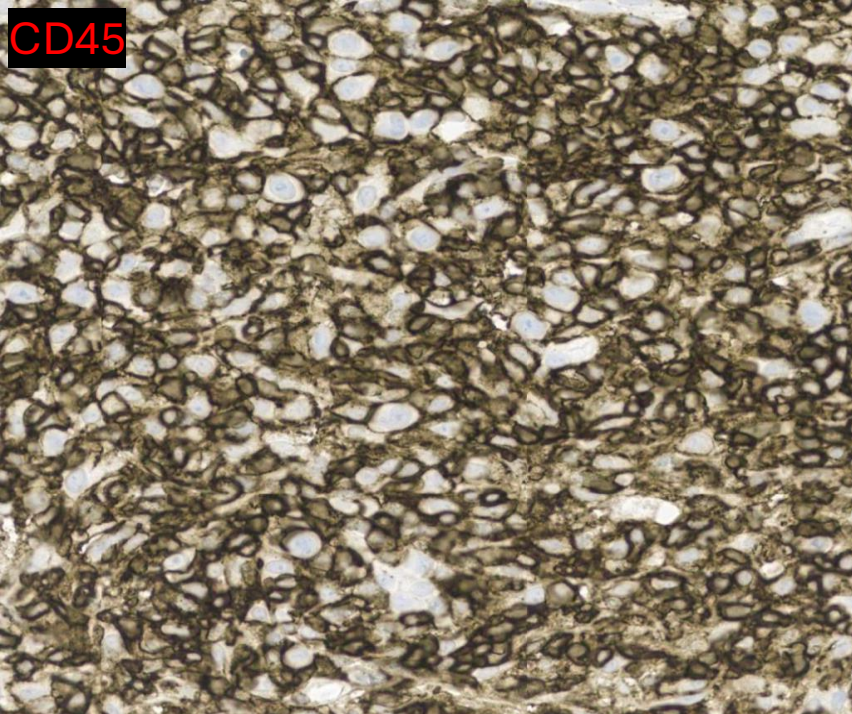
- History of inflammatory myositis
- History of systemic sarcoidosis involving multiple organs
- Has been on long-term immunosuppressive therapy (Humira, methotrexate, tofacitinib, prednisone)
- Skin lesions on leg and arm
- PET CT with hypermetabolic activity in GI tract and mediastinal/hilar lymph nodes
- No fever, night sweats, or weight loss

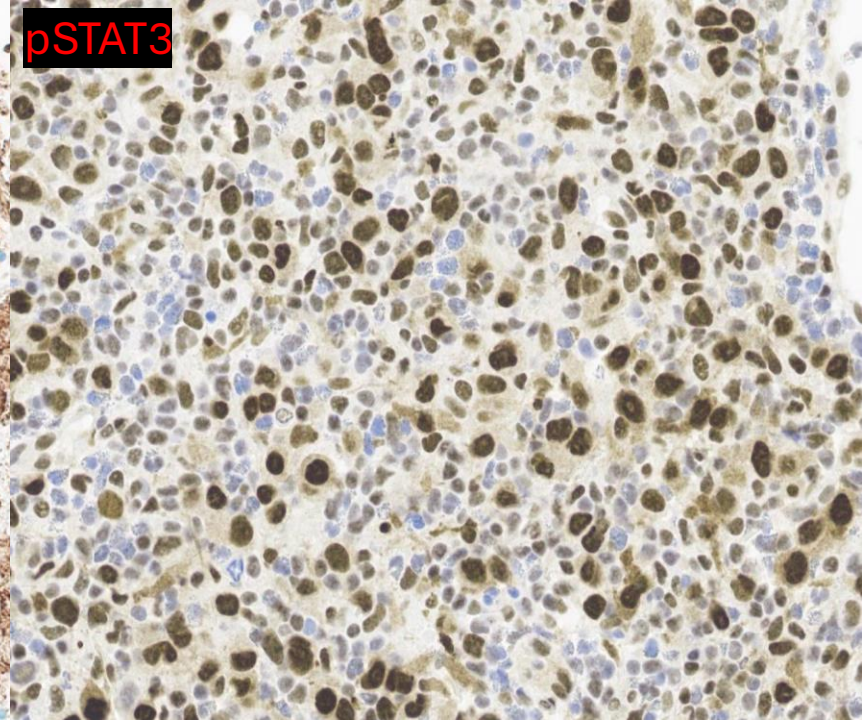
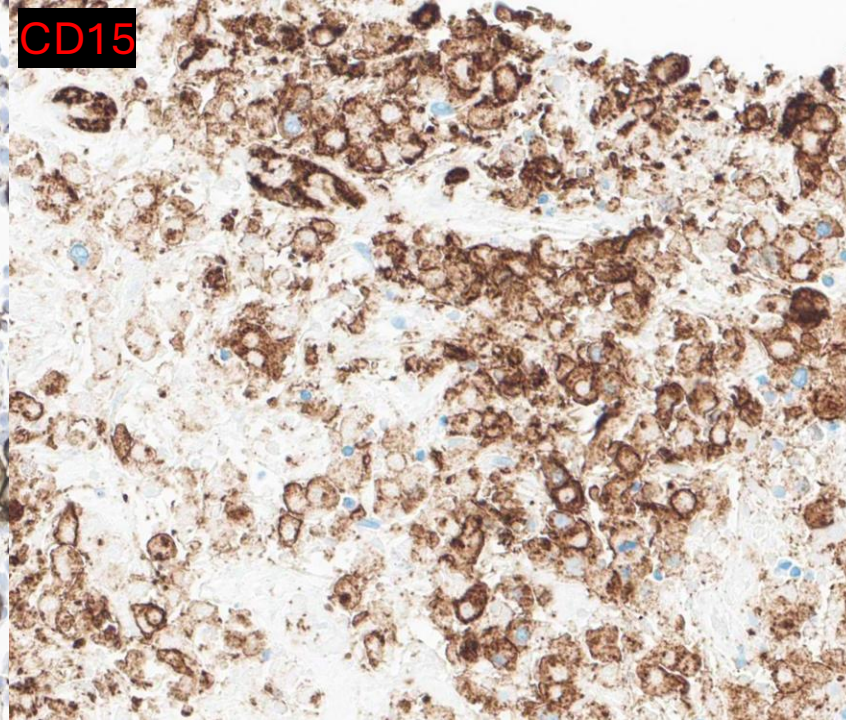
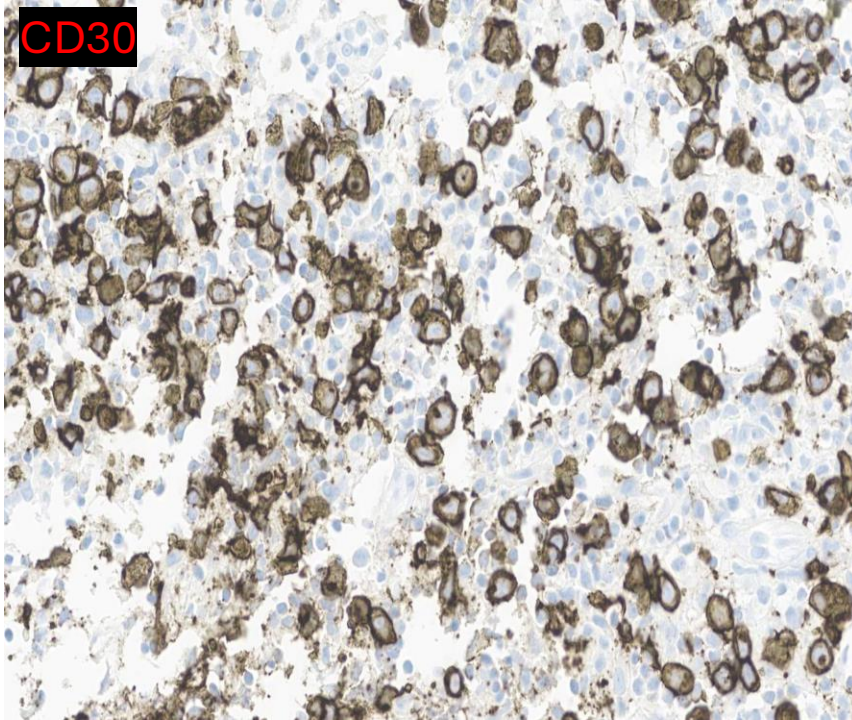


Mediastinal LN Bx

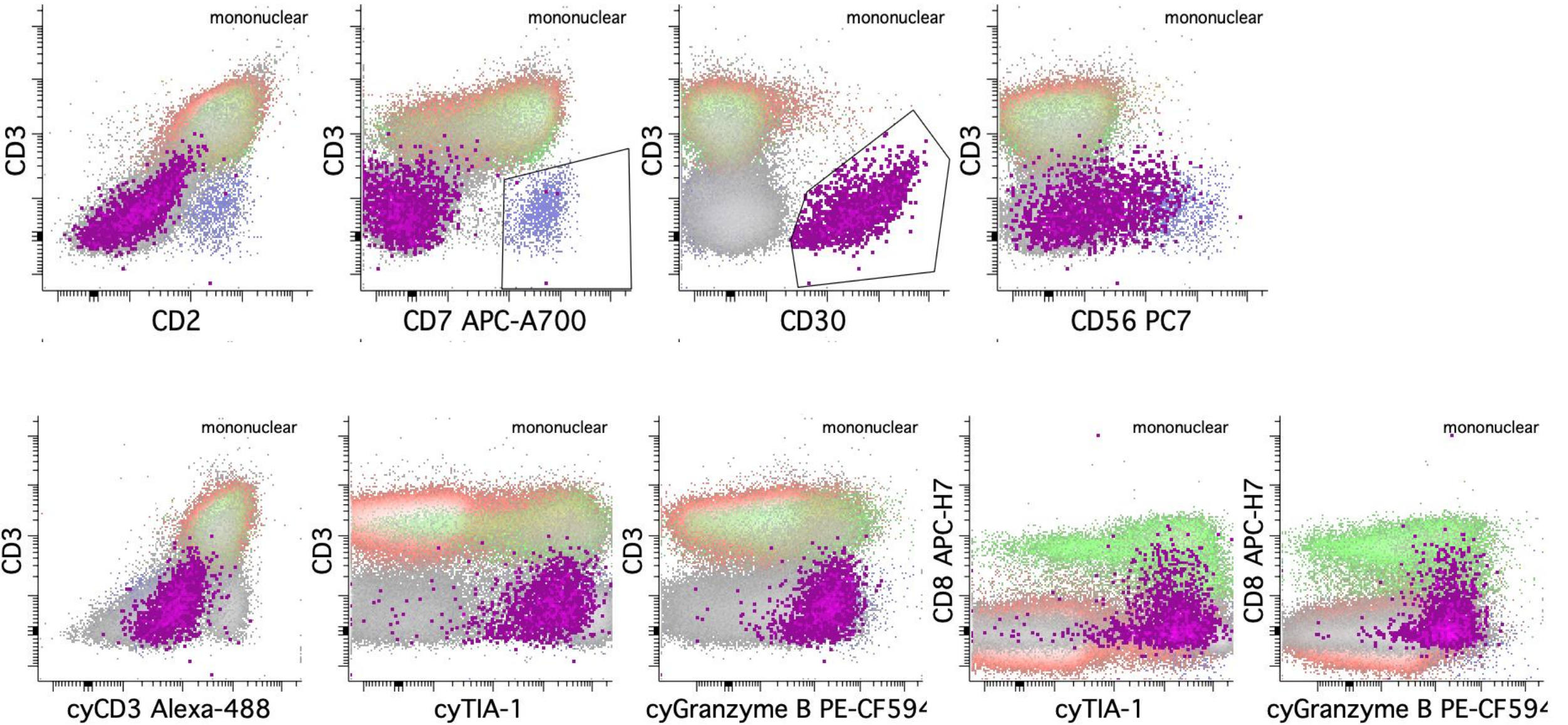








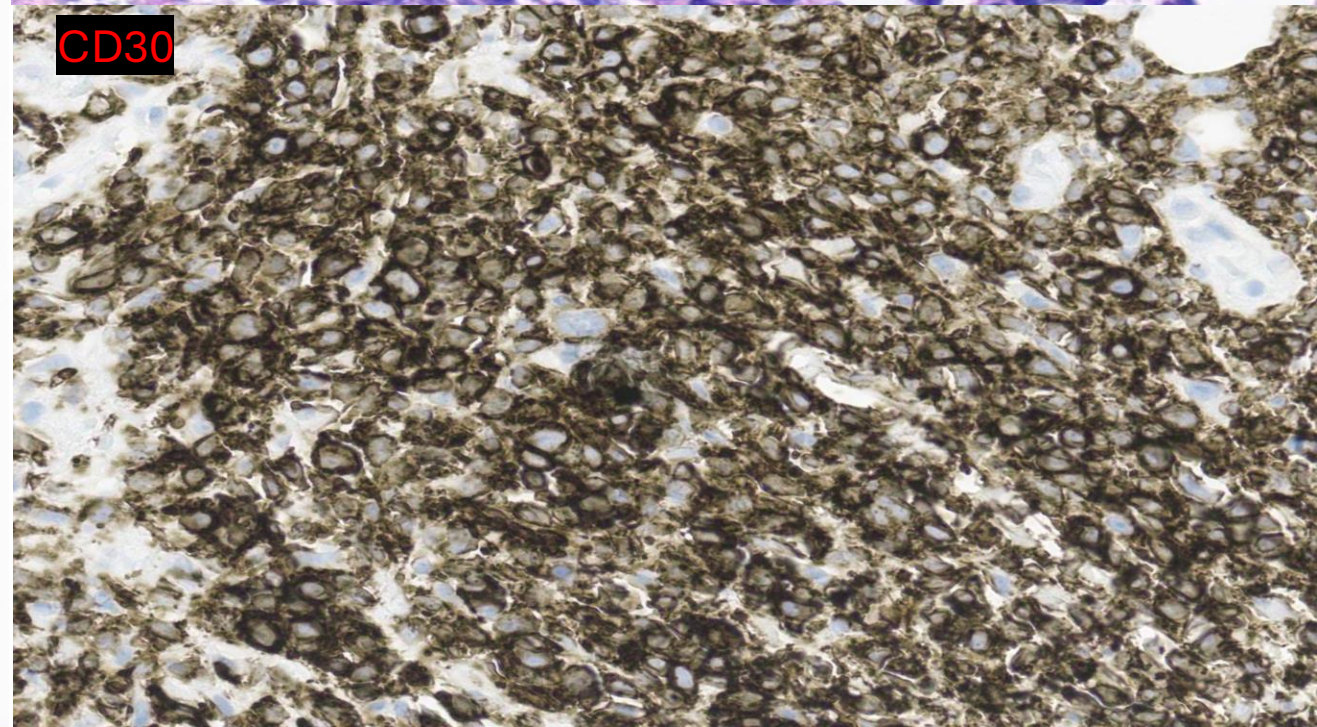
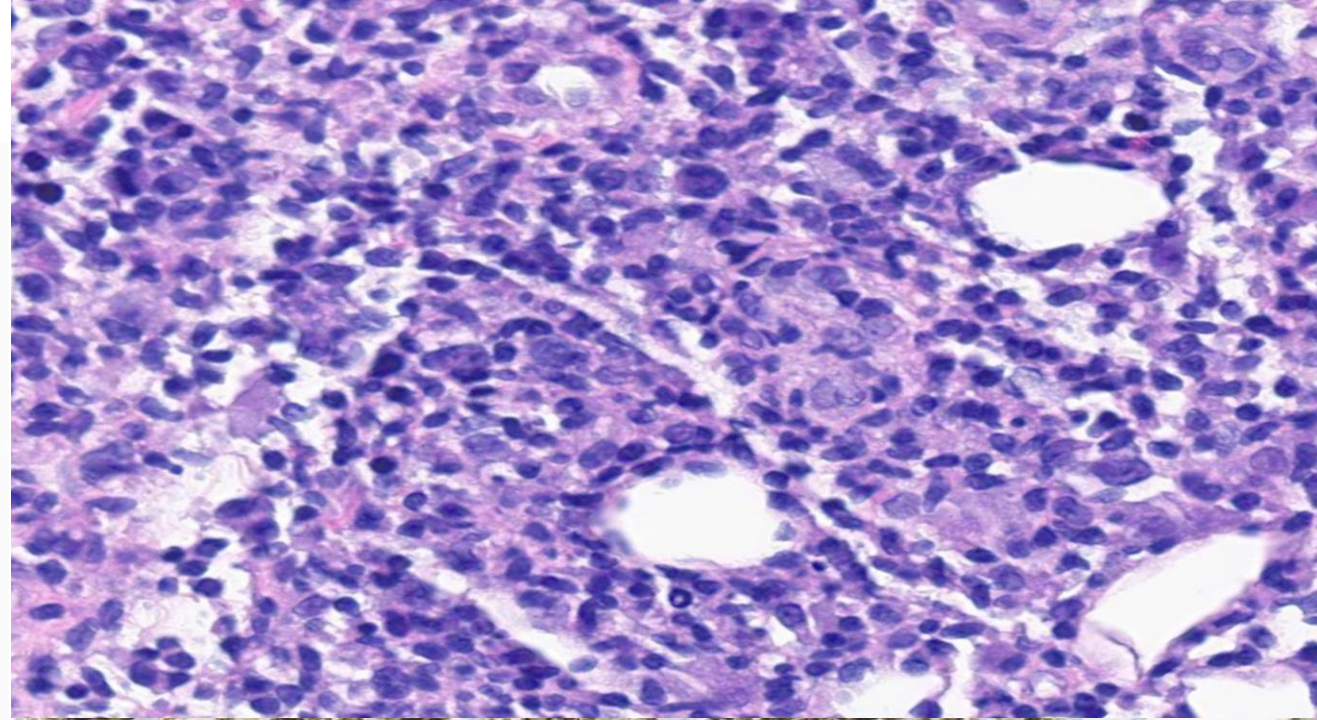
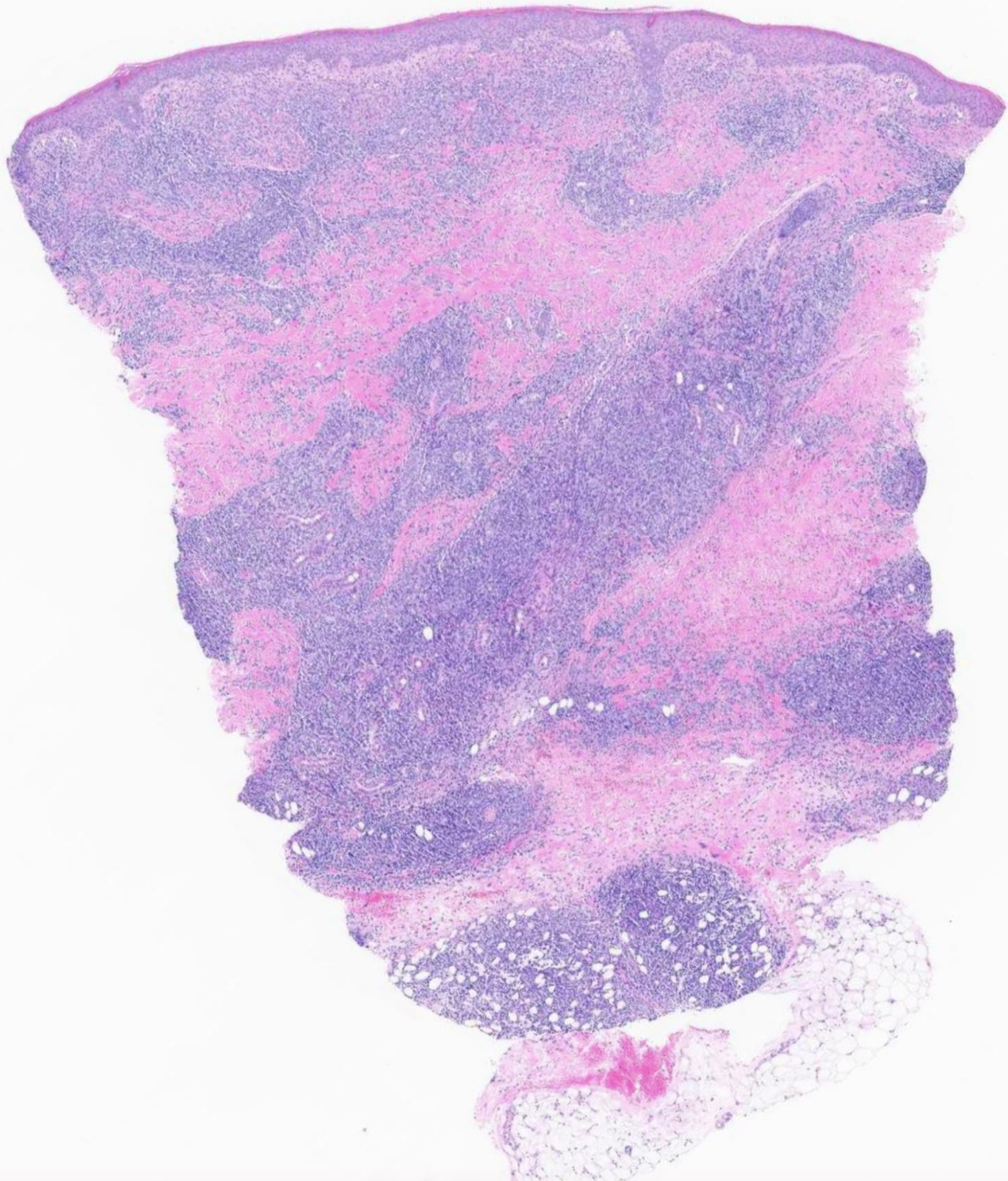
Flow Cytometry




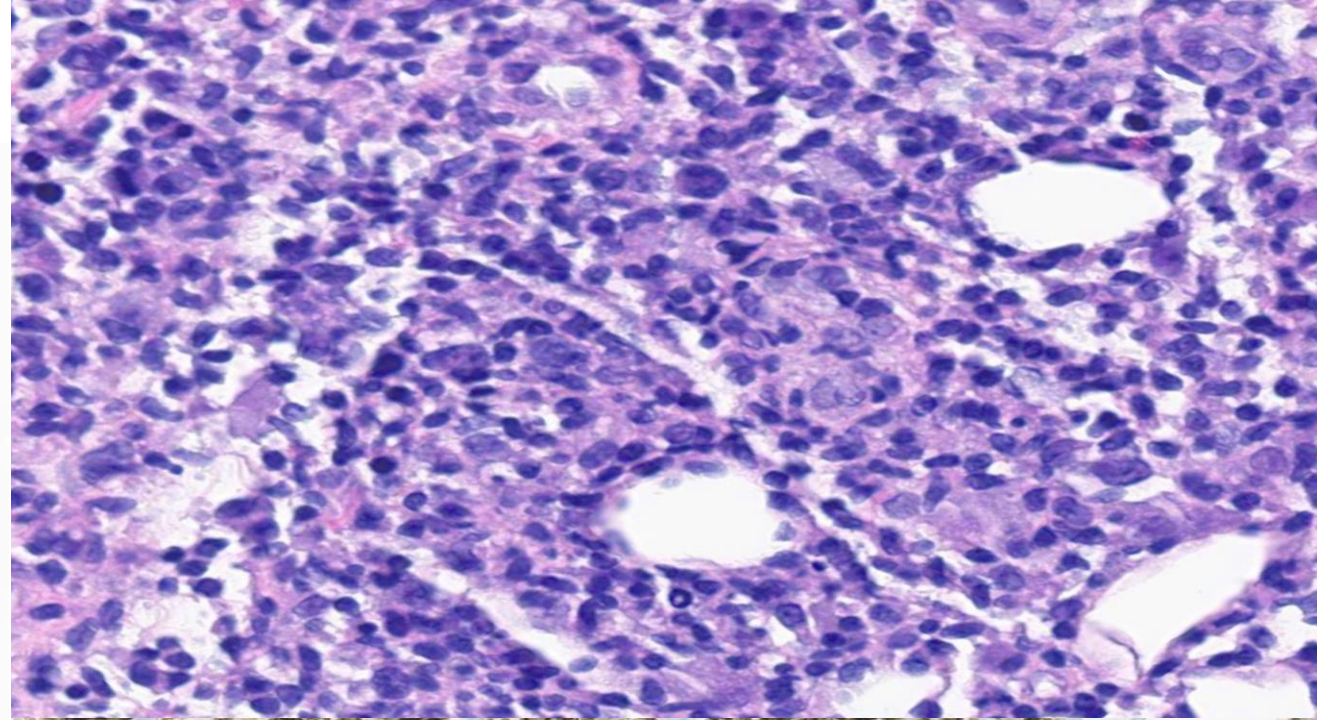
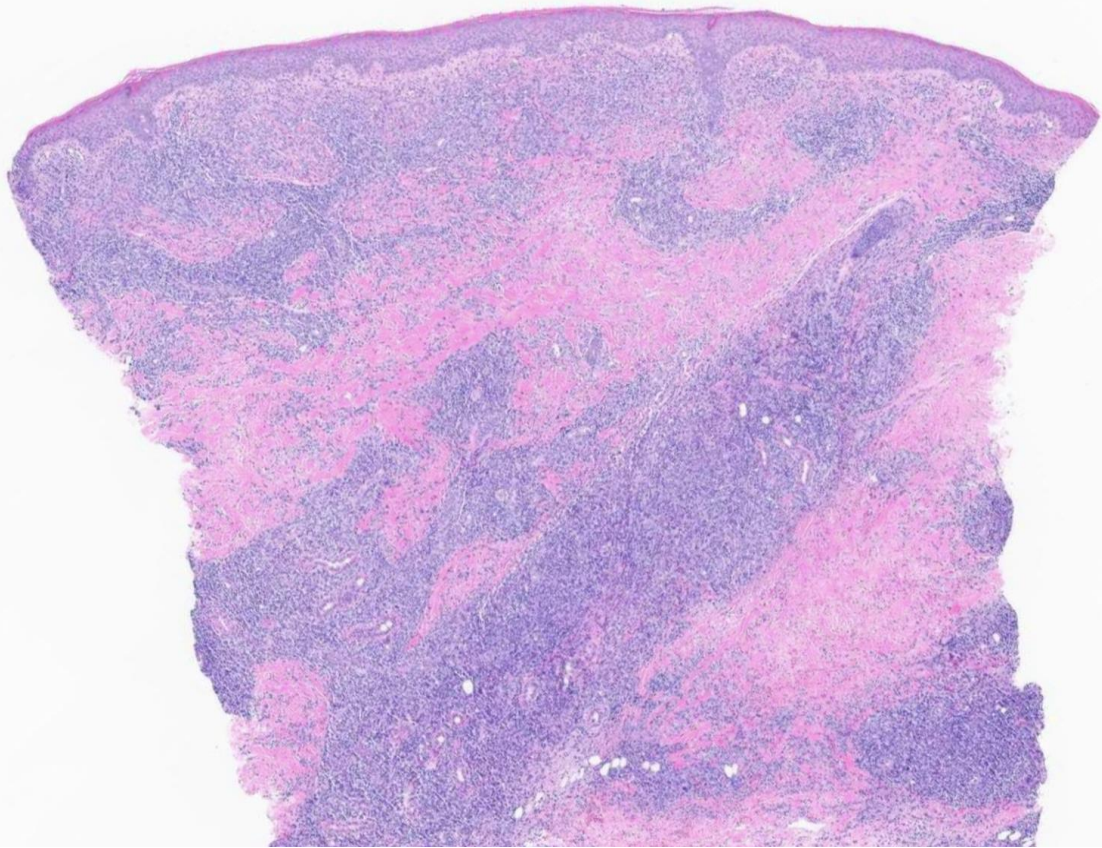
Final Diagnosis

- CD30 positive T-cell lineage lymphoma, most consistent with ALK-negative anaplastic large cell lymphoma.

Left Forearm, Punch Bx

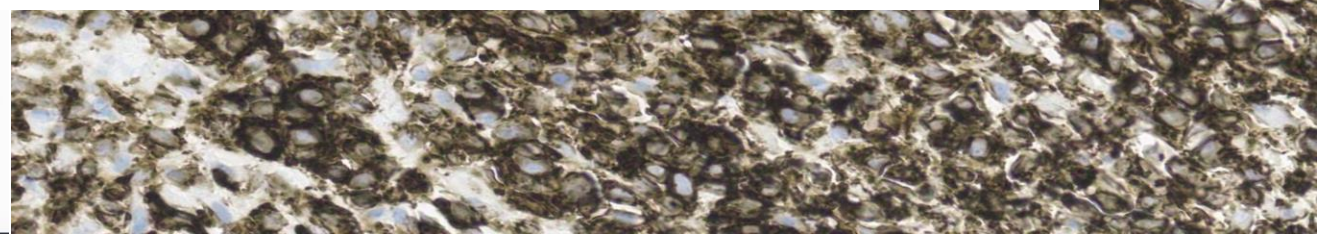
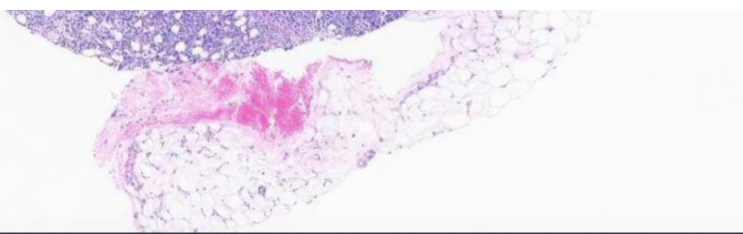


Left Forearm, Punch Bx



Final Diagnosis

CD30 positive T-cell lineage lymphoma, most consistent with ALK-negative anaplastic large cell lymphoma.



Punch Bx Molecular/Cytogenetic Findings

FISH

NO EVIDENCE of *ALK* (2p23.2) rearrangement

NO EVIDENCE of *IRF4/DUSP22* (6p25.3) rearrangement

NO EVIDENCE of *TP63* (3q28) rearrangement

ARCHER FusionPlex (RNA based fusion assay)

POSITIVE FOR THE FOLLOWING GENE FUSIONS:

TFG::JAK2 fusion

Molecular studies (468 gene panel)

POSITIVE FOR THE FOLLOWING SOMATIC ALTERATIONS IN THE INVESTIGATIONAL PANEL:

1. CUX1 (NM_181552 - 7q22.1) Gain (Fold Change: 1.6) (Note: 3)
2. AR (NM_000044) exon4 p.I665S (c.1994T>G)
3. JAK2 (NM_004972) - CMSS1 (NM_032359) rearrangement: t(3;9)(p12.1;p24.1)(chr3:g.99562327::chr9:g.5078749)
4. JAK2 (NM_004972) rearrangement: t(3;9)(q12.2;p24.1)(chr3:g.100448666::chr9:g.5078983) (Note: 2)

POSITIVE FOR THE FOLLOWING CHROMOSOMAL LEVEL ALTERATIONS DETECTED IN CLINICALLY VALIDATED ARMS:

5. Chromosome 7q Loss

Notes:

1. Allele specific copy number analysis by FACETS is suggestive of multiple chromosomal level losses and/or gains (either partial or complete), involving the following regions: gains: 6p, 17q; losses: 7.
2. **The JAK2 rearrangement is a translocation with a breakpoint in intron 16. This event likely represents the JAK2-TFG fusion detected in M25-0321903 and M25-03331120.**

Final diagnosis

- ALK negative anaplastic large cell lymphoma with *TFG::JAK2* fusion

Points of discussion

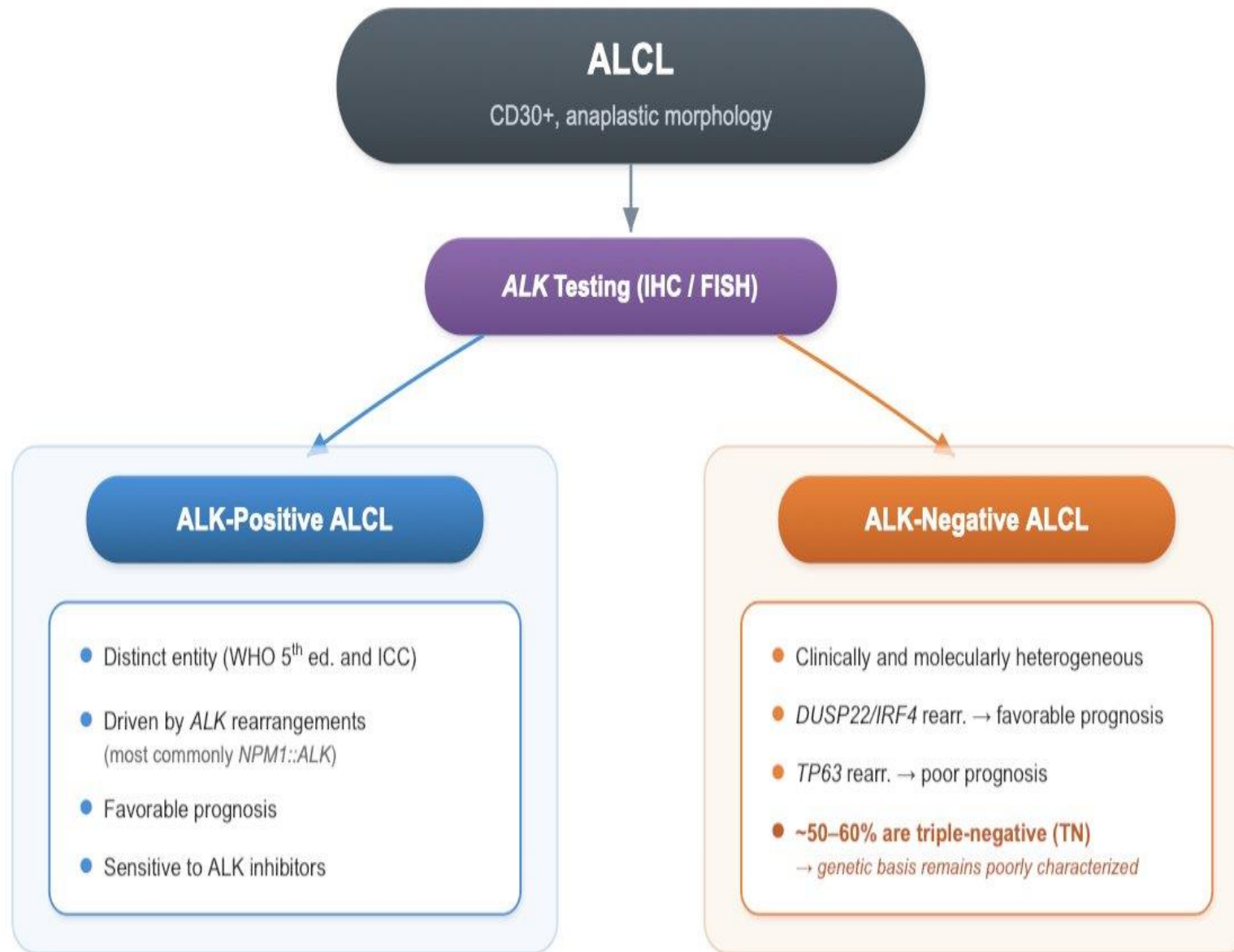
- Distinction between PC-ALCL and systemic ALCL
- Further classification in the rearrangement triple negative ALCLs

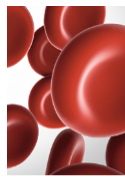
Primary cutaneous ALCL vs systemic ALCL

Feature	Primary cutaneous ALCL	Systemic ALCL
Presentation	Solitary or localized skin lesions, lymph node involvement in draining lymph nodes	Systemic symptoms, may involve lymph nodes and extranodal sites
CD30	Positive	Positive
ALK IHC positivity	Typically not seen in pc-ALCL	Typically only in systemic ALCL
FISH/Cytogenetics	Can have <i>DUSP22</i> rearrangements	Can have <i>ALK</i> , <i>DUSP22</i> , and <i>TP63</i> gene rearrangements

ALK and *TP63* rearrangements typically favor a systemic ALCL

DUSP22 rearrangements seen in both and not helpful for distinction on their own





LYMPHOID NEOPLASIA

Gene expression profiling reveals 2 overarching types of ALCL with distinct targetable biology: an LLMPP study

Andrew L. Feldman,¹ Surendra Dasari,² Lisa M. Rimsza,³ David W. Scott,⁴ Naoki Oishi,^{1,5} Guangzhen Hu,¹ Pedro Farinha,⁶ Catalina Amador,⁷ Elias Campo,⁸ Wing C. Chan,⁹ James R. Cook,¹⁰ Jan Delabie,¹¹ Kai Fu,¹² Timothy C. Greiner,¹³ Laura K. Hilton,⁴ Giorgio Inghirami,¹⁴ Javeed Iqbal,¹³ Elaine S. Jaffe,¹⁵ Ryan D. Morin,⁶ Sarah L. Ondrejka,¹⁰ German Ott,¹⁶ Stefania Pittaluga,¹⁵ Philipp W. Raess,¹⁷ Andreas Rosenwald,¹⁸ Kerry J. Savage,⁶ Graham W. Slack,⁶ Susan L. Slager,² Joo Y. Song,⁹ George W. Wright,¹⁹ Hao-Wei Wang,¹⁵ Yu Zeng,²⁰ Tadashi Yoshino,²¹ Xiaojun Wu,²² Ryan A. Wilcox,²³ Xueju Wang,²⁴ Min Shi,¹ Akira Satou,²⁵ Anamarija M. Perry,²⁶ Roberto N. Miranda,²⁷ L. Jeffrey Medeiros,²⁷ Matthew J. Maurer,² Eric Mou,²⁸ Young-Hyeh Ko,²⁹ Kennosuke Karube,³⁰ Brad S. Kahl,³¹ Liuyan Jiang,³² David L. Jaye,³³ Alejandro A. Gru,³⁴ Laurence de Leval,³⁵ Weina Chen,³⁶ Jennifer R. Chapman,⁷ James R. Cerhan,² Carlos Barrionuevo,³⁷ Stephen M. Ansell,³⁸ and Ahmed A. Aljudi³⁹

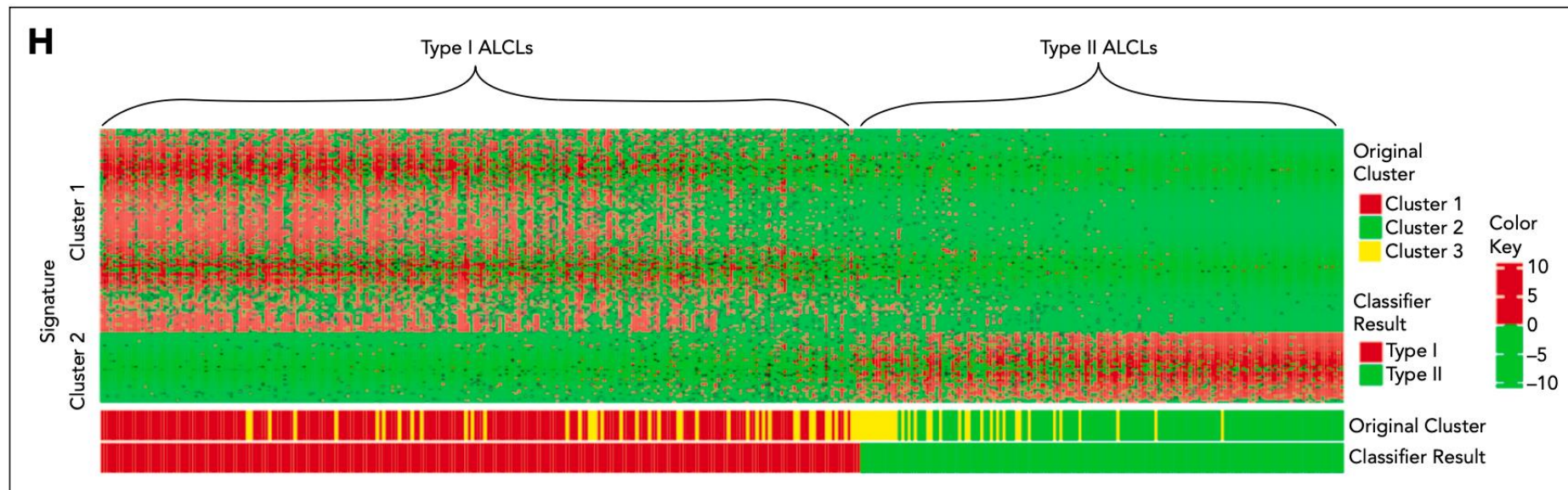
¹Department of Laboratory Medicine and Pathology and ²Department of Quantitative Health Sciences, Mayo Clinic College of Medicine and Science, Rochester, MN; ³Department of Pathology and Laboratory Medicine, The University of Arizona College of Medicine and Science, Tucson, AZ; ⁴Centre for Lymphoid Cancer, BC Cancer, Vancouver, BC, Canada; ⁵Department of Pathology, University of Yamanashi, Yamanashi, Japan; ⁶BC Cancer, Vancouver, BC, Canada; ⁷Department of Pathology and Laboratory Medicine, University of Miami Miller School of Medicine, Miami, FL; ⁸Institute of Biomedical Research August Pi i Sunyer, University of Barcelona, Barcelona, Spain; ⁹Department of Pathology, City of Hope National Medical Center, Duarte, CA; ¹⁰Department of Laboratory Medicine, Cleveland Clinic, Cleveland, OH; ¹¹Department of Laboratory Medicine and Pathobiology, University of Toronto, Toronto, ON, Canada; ¹²Department of Pathology, Roswell Park Cancer Institute, Buffalo, NY; ¹³Department of Pathology and Microbiology, University of Nebraska Medical Center, Omaha, NE; ¹⁴Department of Pathology and Laboratory Medicine, Weill Cornell Medicine, New York, NY; ¹⁵Laboratory of Pathology, Center for Cancer Research, National Cancer Institute, Bethesda, MD; ¹⁶Department of Clinical Pathology, Robert-Bosch-Krankenhaus and Dr Margarete Fischer-Bosch Institute of Clinical Pharmacology, Stuttgart, Germany; ¹⁷Department of Pathology and Laboratory Medicine, Oregon Health and Science University, Portland, OR; ¹⁸Institute of Pathology, University of Würzburg, Würzburg, Germany; ¹⁹Biometric Research Program, Division of Cancer Diagnosis and Treatment, National Cancer Institute, Bethesda, MD; ²⁰Department of Pathology, Tongji Hospital, Tongji University School of Medicine, Shanghai, China; ²¹Department of Pathology, Okayama University Graduate School of Medicine, Dentistry and Pharmaceutical Sciences, Okayama, Japan; ²²Department of Pathology, Johns Hopkins Medicine, Baltimore, MD; ²³Division of Hematology/Oncology, University of Michigan Cancer Center, Ann Arbor, MI; ²⁴Department of Pathology, China-Japan Union Hospital of Jilin University, Changchun, China; ²⁵Department of Pathology and Laboratory Medicine, Nagoya University Hospital, Nagoya, Japan; ²⁶Department of Pathology, University of Michigan, Ann Arbor, MI; ²⁷Department of Hematopathology, The University of Texas MD Anderson Cancer Center, Houston, TX; ²⁸Division of Hematology, Oncology, and Blood & Marrow Transplantation, University of Iowa, Iowa City, IA; ²⁹Department of Pathology, Guro Hospital, Korea University College of Medicine, Seoul, Korea; ³⁰Department of Pathology and Laboratory Medicine, Nagoya University, Nagoya, Japan; ³¹Department of Medicine, Washington University, St Louis, MO; ³²Department of Laboratory Medicine and Pathology, Mayo Clinic College of Medicine and Science, Jacksonville, FL; ³³Department of Pathology and Laboratory Medicine, Emory University School of Medicine, Atlanta, GA; ³⁴Dermatopathology Section, Columbia University Irving Medical Center/New York–Presbyterian, New York, NY; ³⁵Institute of Pathology, Department of Laboratory Medicine and Pathology, Lausanne University Hospital and Lausanne University, Lausanne, Switzerland; ³⁶Department of Pathology, The University of Texas Southwestern Medical Center, Dallas, TX; ³⁷Departamento de Patología, Instituto Nacional de Enfermedades Neoplásicas, and Facultad de Medicina, Universidad Nacional Mayor de San Marcos, Lima, Peru; ³⁸Division of Hematology, Mayo Clinic College of Medicine and Science, Rochester, MN; and ³⁹Department of Pathology, Children’s Healthcare of Atlanta, Atlanta, GA

Study Design

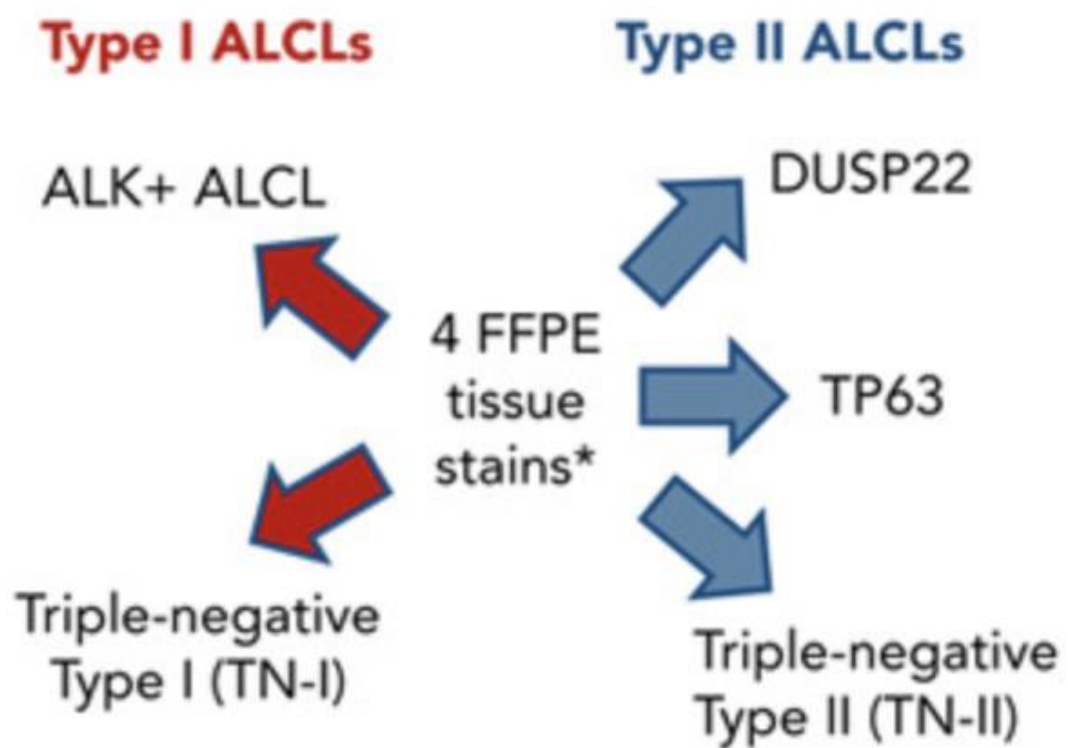
- **Retrospective, multi-institutional cohort from the LLMPP international consortium**
- **RNA sequencing of 393 ALCL patients**
 - Unsupervised and supervised gene expression analyses
- Genetic subtyping by FISH (*ALK*, *DUSP22*, *TP63*)
- IHC for pSTAT3 (Y705) on 689 cases

Two Molecular Types: Type I and Type II (Fig 1H)

- ALCLs fundamentally segregate into two overarching gene expression patterns



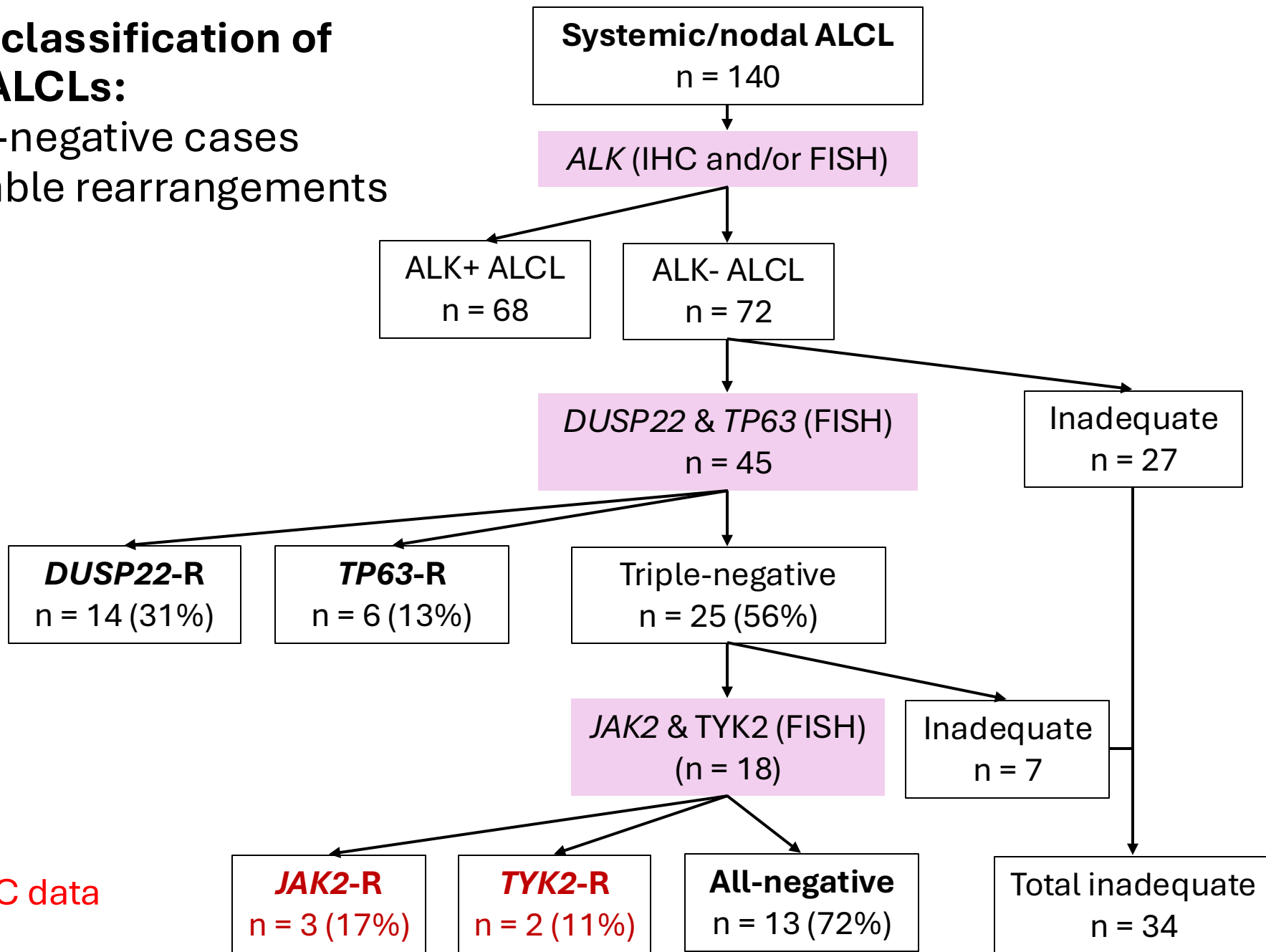
	TYPE I	TYPE II
Key pathway	JAK-STAT3, tyrosine kinase signaling	Epigenetic dysregulation (EZH2), cell cycle, cholesterol biosynthesis
pSTAT3 status	Positive (92%)	Negative (89%)
Subtypes included	ALK+, BIA, TN-I	DUSP22, TP63, TN-II



*Immunohistochemistry for ALK and pSTAT3 and fluorescence *in situ* hybridization (FISH) for *DUSP22* and *TP63*. FFPE: formalin-fixed, paraffin-embedded.

Molecular subclassification of 140 systemic ALCLs:

Majority of ALK-negative cases harbor identifiable rearrangements



Unpublished MSKCC data
Please do not share

ALCL

**Kinase Fusion Positive
(STAT3 Transcriptional Program)**

ALK Rearrangement

TYK2 Rearrangement

JAK2 Rearrangement

Kinase Fusion Negative

DUSP22 Rearrangement

TP63 Rearrangement

No rearrangements

Unpublished MSKCC data
Please do not share

References

- Feldman, A. L., Dasari, S., Rimsza, L. M., Scott, D. W., Oishi, N., Hu, G., ... & Aljudi, A. A. (2026). Gene expression profiling reveals 2 overarching types of ALCL with distinct targetable biology: an LLMPP study. *Blood*, 147(11), 1199-1214.
- Morris, S. W., Kirstein, M. N., Valentine, M. B., Dittmer, K. G., Shapiro, D. N., Saltman, D. L., & Look, A. T. (1994). Fusion of a kinase gene, ALK, to a nucleolar protein gene, NPM, in non-Hodgkin's lymphoma. *Science*, 263(5151), 1281-1284.
- Parrilla Castellar, E. R., Jaffe, E. S., Said, J. W., Swerdlow, S. H., Ketterling, R. P., Knudson, R. A., ... & Feldman, A. L. (2014). ALK-negative anaplastic large cell lymphoma is a genetically heterogeneous disease with widely disparate clinical outcomes. *Blood, The Journal of the American Society of Hematology*, 124(9), 1473-1480.
- Alaggio, R., Amador, C., Anagnostopoulos, I., Attygalle, A. D., Araujo, I. B. D. O., Berti, E., ... & Xiao, W. (2022). The 5th edition of the World Health Organization classification of haematolymphoid tumours: lymphoid neoplasms. *Leukemia*, 36(7), 1720-1748.
- Crescenzo, R., Abate, F., Lasorsa, E., Gaudiano, M., Chiesa, N., Di Giacomo, F., ... & Inghirami, G. (2015). Convergent mutations and kinase fusions lead to oncogenic STAT3 activation in anaplastic large cell lymphoma. *Cancer cell*, 27(4), 516-532.
- Luchtel, R. A., Dasari, S., Oishi, N., Pedersen, M. B., Hu, G., Rech, K. L., ... & Feldman, A. L. (2018). Molecular profiling reveals immunogenic cues in anaplastic large cell lymphomas with DUSP22 rearrangements. *Blood, The Journal of the American Society of Hematology*, 132(13), 1386-1398.
- Velusamy, T., Kiel, M. J., Sahasrabudde, A. A., Rolland, D., Dixon, C. A., Bailey, N. G., ... & Elenitoba-Johnson, K. S. (2014). A novel recurrent NPM1-TYK2 gene fusion in cutaneous CD30-positive lymphoproliferative disorders. *Blood, The Journal of the American Society of Hematology*, 124(25), 3768-3771.