Two Powerful Imaging Tools Make Their Debut in the United States

Technology continues to hold center stage at New York Eye and Ear Infirmary of Mount Sinai (NYEE), underscored by the recent arrival of two cutting-edge imaging devices: a tear film analyzer and an optical coherence tomography (OCT) Doppler.

"Both devices are examples of what keeps us in the forefront of ophthalmic research," says Paul A. Sidoti, MD, Chair of Ophthalmology, NYEE. "They are highly sophisticated research and clinical tools that will generate important new information to help us better understand disease processes and thus more accurately diagnose patients and assess the impact of their treatments."

The Tear Film Analyzer

It's hard to overstate the importance of the tear film: the first ocular system through which light must pass and the eye's first encounter with the ambient environment. Yet deciphering the complexity of its three layers (lipid, aqueous, and mucoid) to determine the best type and duration of treatment for disturbances that afflict the tear film—like dry eye and ocular surface disease—has always been imprecise.

That's about to change as NYEE becomes the first clinical site in the United States with a tear film analyzer. "This device will allow us to image, separate, and quantify the thickness of each component layer of the tear film," explains Masako Chen, MD, Assistant Professor of Ophthalmology, Icahn School of Medicine at Mount Sinai. "Having quantifiable measurements of the tear film will allow us to track patients over time and see how they respond to different therapies. It could have a significant impact on our approach to dry eye and ocular surface disease."

Initially, the tear film analyzer will play a critical research role, enabling Dr. Chen to study a variety of dry eye and ocular surface pathologies from samples she has collected from her patients. "Observing normal versus abnormal conditions will give a lot of comparative data, which eventually could be used to tailor our therapies to patients," notes Dr. Chen, who is both a scientist and a clinician specializing in cornea and ocular surface diseases.

"The tear film involves all aspects of ophthalmology, which is why we were determined to bring it here for use by all our clinical departments," says Richard B. Rosen, MD, Vice Chair and Director of Ophthalmology Research at NYEE, who initially approached Advanced Optical Technologies, Ltd. (AdOM), the small Israeli company that developed the device. "It will change how we treat patients with dry eye especially, because by measuring very fine changes, the tear film analyzer will give us quantitative and objective feedback on the effectiveness of all of our ocular treatments."

OCT Doppler

OCT Doppler imaging was first demonstrated 25 years ago, but, thanks to recent innovations and algorithms, has become a more versatile technology with the potential to significantly change glaucoma research and patient treatment. NYEE has been an important part of that development, working closely with Topcon, a well-known developer of ocular imaging devices, to bring OCT Doppler into the clinical space by allowing for high-resolution visualization of blood flow through tiny vessels and the mapping of vascularization networks in humans.

"We've known that blood flow likely plays an important role in the development of glaucoma, but for the first time, OCT Doppler will allow us to take a more in-depth look through our research at the velocity and amount of blood flow to determine if any changes to these metrics occur before we actually see structural damage to the eye from glaucoma," says Tak Yee Tania Tai, MD, Associate Professor of Ophthalmology at Icahn Mount Sinai, who specializes in glaucoma research and patient management. "This is an exciting development because it could potentially lead to early diagnosis and treatment of a disease that robs so many people of their sight."

Housed within the Shelley and Steven Einhorn Clinical Research Center at NYEE, the OCT Doppler is expected to shed valuable new light on the recovery dynamics of retinal vein occlusion, measuring how blood flow is reestablished to normal levels following a vascular blockage in the retina, and the impact of blood flow variations in many diseases other than glaucoma, including diabetic retinopathy, macular degeneration, and central serous retinopathy.

Tear Film Analyzer

Masako Chen, MD

Patient Name / ID	_ /	Eye	
Age / Gender	/	Date / Time	/
TFI operator			
Measurement Quality Parameters	Test Duration (sec)	20.042	> 6.0
	Signal Score (%)	0.05	> 0.0273
	Position Score	3.26	< 21
	Data Continuity (sec)	9.9	> 2.5
MALT	Mucus-Aqueous Layer Thickness	4548.7	nm
MALTR	Mucus-Aqueous Thinning Rate	-480.000	nm/sec
LLT	Lipid Layer Thickness	38.8	nm
LBUT	Lipid Break-Up Time	4.140	sec
IBI	Inter-Blink Interval	10.28	sec
LMU	Lipid Map Uniformity	9.6	squared nm

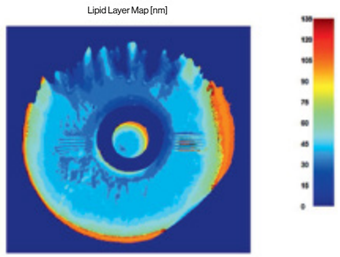

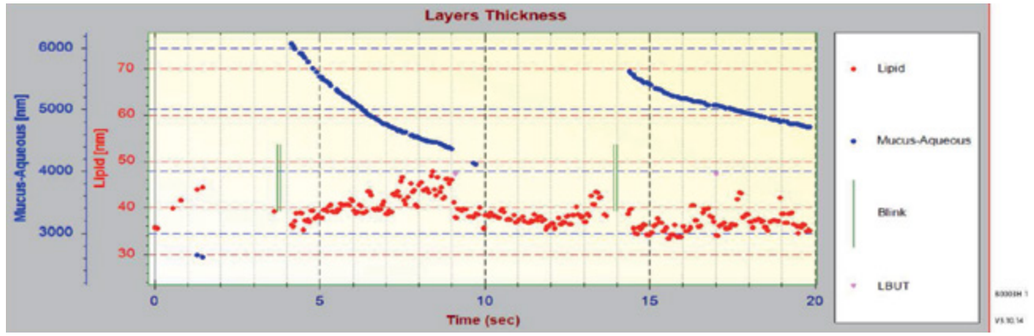

Example of a report from the Tear Film Analyzer showing thickness of the tear film inner layers (muco-aqueous layer and lipid layer) using spectral interference technology

OCT Doppler

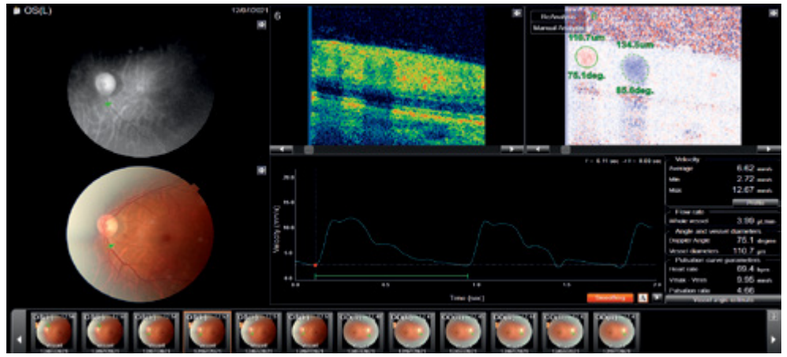

Tania Tai, MD

Measurement of retinal blood flow biomarkers in a healthy subject using OCT Doppler: **Upper Right:** Cross-sectional image with the artery highlighted in red and the vein highlighted in blue; **Bottom Left:** Color fundus photo indicating selected blood vessel (green arrow); **Bottom Right:** Blood vessel analysis of the selected artery with average velocity, blood flow rate of the selected artery, vessel diameter, heart rate, and other parameters outlined on the right