NeuroLogic

JOHNS HOPKINS MEDICINE

NEWS FOR PHYSICIANS FROM THE DEPARTMENTS OF NEUROLOGY AND NEUROSURGERY

SPRING 2013

A Fond Farewell

Things have changed over the last 45 years at Johns Hopkins, says neurologist and pediatric epilepsy specialist **Patti Vining**. When she started medical school here in 1968, she was one of just 10 women in her class. Now, like most medical schools across the country, the students are equally split between the sexes.

There also was no Department of Neurology then—a welcome addition that came along the year after she started her medical training. "I got to see the formation of the department while I was a student," she says.

Things have also changed quite a bit for pediatric neurosurgeon **Ben Carson**. When he came to Hopkins as an intern in 1977, there was no such thing as the current 80-hour workweek cap. "We frequently worked well over 100 hours a week," he remembers.

He was also one of the few African-American physicians then at Johns Hopkins. "Every time I'd go into the wards," he says, "people would think I was an orderly or respiratory therapist. I knew they were just saying that based on past experience. Once I corrected them, they never made that mistake again."

Both doctors, after rising over the years from trainees to well-respected experts in their fields, will be retiring this summer. Retiring along with them is Carson's longtime physician assistant (PA), **Carol James**.

James started her Johns Hopkins Hospital career in 1967 as a medical secretary and decided after several years that she wanted to work more closely with patients. After attending a physician assistant program at Yale, she returned and took a job in the neurosurgical service.

When Carson became the chief resident of that department, James remembers that she and Carson "really clicked." They've been working together ever since.

"It's been 31 years of collaboration, growing, learning and doing," she says. The two have been together so long that they finish each other's sentences. "He's like my work husband," James adds. "I spend much more time with him than with my real husband at home."

Over the years that the two have worked together, Carson and James count plenty of highlights: for example, reviving hemispherectomies—complex operations that involve removing half of the brain—as a viable treatment for epilepsy and separating twins conjoined at the head.

"IT'S BEEN 31 YEARS OF COLLABORATION, GROWING, LEARNING AND DOING."

– CAROL JAMES

Carol James, Ben Carson and Patti Vining, whose careers have spanned decades at Johns Hopkins, are all retiring over the next several months.

Vining's time at Johns Hopkins has been similarly prolific, she says. Through a longtime collaboration with John Freeman, who created and directed the pediatric neurology service, the two wrote a book that remains the authoritative guide on pediatric epilepsy for families and has been published in several editions.

"We helped empower families and change the perception of what epilepsy in children is all about," she says. "The majority of people with epilepsy do fine, and that's really been reflected in our books."

She and Freeman helped revive hemispherectomies as well, showing that they can be safe and effective for patients with intractable seizures. The pair also helped popularize the ketogenic diet for epilepsy.

Pediatric neurology and neurosurgery has grown tremendously since Vining, Carson and James started their tenures here. Practically loners in their departments at the beginning, now there are three pediatric neurosurgeons and eight pediatric neurologists, all considered leaders in their field. Several other specialists now support the departments, including pediatric vascular neurosurgeons and pediatric peripheral nerve neurosurgeons. Six PAs strengthen pediatric neurology and neurosurgery even further.

As the three step down, the departments are helping to fill the void with new experts and helping existing faculty move up, including **George Jallo**, a world renowned neurosurgeon who is now the director of pediatric neurosurgery and will now hold Carson's former title, the Evelyn Spiro, R.N. Professor in Pediatric Neurosurgery.

"These three have made incredible contributions, providing expertise and helping children in ways no one had dreamed of 30 years ago," says **Henry Brem**, director of the Department of Neurosurgery. "They have created some of the best neurology and neurosurgery programs in the nation, which are flourishing." ■

Treating Headaches in the Youngest Patients

Christopher Oakley is the new director of the Johns Hopkins Pediatric Headache Clinic.

Headaches are the most frequent reason for referrals to pediatric neurologists, yet very few specialize in this condition. Working to fill that void are **Christopher Oakley** and his physician assistant, **Candie Marchand**. The two recently started Johns Hopkins' Pediatric Headache Clinic, one of the few centers in the country that specifically treats headaches in children.

Most of Oakley and Marchand's patients have nearly daily, primary headaches with no known etiology of tumor, infection, trauma or other causes. For the vast majority, Oakley says, the most important part of his workup is taking a detailed history.

"I spend about 45 minutes talking with each patient," he says. "If I had my say, I'd probably be spending hours. It's critical to truly understand each patient and family and build a relationship."

It's that solid relationship that makes patients more likely to follow his treatment recommendations on the sometimes-long road to easing chronic headaches, Oakley explains. While researchers are working toward gaining a better understanding of headaches, it's still unclear what causes them, and there is no cure—only ways to manage the pain and prevent onset.

Working toward that goal, Oakley and Marchand use a three-pronged approach. The team first helps patients attain a healthy lifestyle, complete with maintaining good hydration, getting enough exercise, not skipping meals, eating a healthy diet and getting enough rest. Establishing good habits can help prevent headaches before they start, Oakley says.

Next, based on each patient's lifestyle, they suggest some alternative therapies, such as physical therapy, meditation, biofeedback and behavioral therapy. "There's also good evidence that some supplements have benefits," he says. For example, some of his patients take magnesium, vitamin B2, coenzyme Q10, feverfew and butterbur, all shown to lessen headaches in clinical trials.

Finally, if these approaches don't significantly reduce the number and severity of a patient's headaches, Oakley and Marchand prescribe preventive drugs for daily use and abortive drugs for acute headaches.

"I stress to patients and their families that medicines are not a cure. Our best hope is to decrease the headache frequency and severity," he says. "If we decrease their headaches by 50 percent, that's a success."

At the new center, Oakley and Marchand see patients together for the initial visit, and Marchand sees them for follow-up visits, tracking the effects of lifestyle changes and adjusting medicines, if necessary. The team approach allows more access to keep the wait time for appointments shorter and help kids feel better sooner.

"I tell families up front that I don't focus on how many headaches kids have and what they feel like. I focus on disability and dysfunction," Oakley says. "I want kids to get back to themselves and feel normal again." ■

Information: 410-955-4259

Curing Chordomas

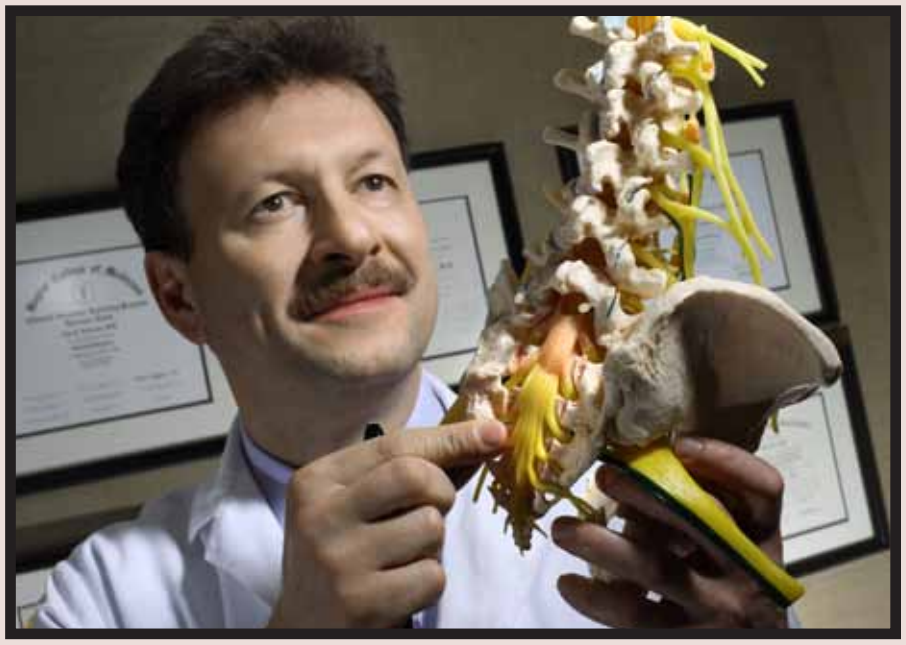

Ziya Gokaslan and his colleagues have a unique expertise in removing chordomas, tumors that are often exceptionally difficult to treat.

The chances of being diagnosed with a chordoma are literally one in a million. These rare cancers are thought to arise from remnants of the notochord, cartilage that serves as a scaffold for the backbone during development. When genes for proliferation turn on by mistake later in life, these residual cells can form slow-growing but relentless tumors that can be fatal if they aren't removed.

While these tumors can occur anywhere in the skull or spine, having a chordoma in the sacrum comes with its own special set of challenges, says neurosurgeon **Ziya Gokaslan**. "There, the tumor can affect nerves for bowel, bladder and sexual function," he explains. "If the tumor isn't removed properly, these functions can be permanently harmed."

Because chordomas usually present as a soft tumor contained in a bag of fluid, it's critical to remove the tumor in one piece without breaking the bag. If its contents are spilled, Gokaslan says, malignant cells can take up residence in the surrounding tissue and metastasize throughout the body, making a cure impossible at that point.

Gokaslan and his colleagues have amassed significant experience in treating chordomas, including very large tumors that necessitate removal of the entire sacrum. The team has developed techniques that can spare critical nerves if the tumor location is amenable, keeping bowel, bladder and sexual function intact.

When Gokaslan and his team need to remove a patient's entire sacrum, the lumbar spine becomes dissociated from the hips and pelvis, he explains, requiring total reconstruction with multiple screws, rods and bone grafts. These operations can take up to 16 hours and may need to be completed over two days.

For such large surgeries, wound closure is a critical element, he adds. Gokaslan and his team regularly work with plastic surgeons skilled in techniques to repair these wounds. These complicated procedures often require pulling an island of vascularized tissue from the abdomen through to the other side, replacing tissue removed during surgery.

To develop better treatments, Gokaslan and his colleagues are conducting basic research to understand why these tumors arise. Recent findings suggest that small RNAs might be able to block the expression of tumor-specific genes in chordoma cells, offering a way to control disease in patients whose tumors couldn't be removed completely.

"We're hoping to take some of these discoveries from the lab," he says, "and move them to the bedside to increase our cure rate even further." ■

Information: 410-955-4424

Doing No Harm for Ischemic Stroke

Tissue plasmogen activator (tPA) has been a lifesaver for thousands of ischemic stroke patients over the past decade. When this clot-busting drug is administered intravenously within 4.5 hours after stroke onset, patients are significantly more likely to survive and even have a full recovery.

However, says stroke neurologist **Richard Leigh**, only a minority of patients qualify for tPA now using current guidelines. Because most people who've had an ischemic stroke arrive for treatment past the time frame when tPA is considered effective and safe, the vast majority of ischemic stroke patients must undergo more aggressive treatments, such as pulling the clot out mechanically through a catheter threaded from the groin or directly injecting tPA into the brain—procedures that, while effective, come with significant risks.

That's because the longer a stroke goes on, Leigh explains, the more damage occurs to the blood-brain barrier, the unique shielding of blood vessels that limits the passage of molecules from the bloodstream into the brain. Once this security system has been breached, tPA use might cause hemorrhaging in the brain. In fact, roughly 6 percent of patients treated with tPA within the optimal window still have hemorrhaging because their blood-brain barrier has already sustained too much damage.

"We want to help patients, but we need to make sure our treatments don't make things worse," Leigh says.

To help solve this conundrum, Leigh and his colleagues recently developed a new way to characterize blood-brain barrier damage in ischemic stroke patients through a novel way of looking at standard MRI scans. Before they undergo aggressive procedures to remove clots, stroke patients traditionally receive MRIs to estimate the risks and benefits of the recommended approach. The researchers developed novel software that uses these MRI images already taken and overlays them with calculations that more precisely measure blood-brain barrier damage, allowing them to get a better estimate of which patients would benefit from tPA, even after the recommended treatment window.

continued on page 4

Enhanced software recently developed by Richard Leigh and his colleagues could help make clot-busting treatment safer and more widely available for stroke patients.

Jon Weingart and other Hopkins neurosurgeons have used their new intraoperative MRI in more than 60 cases.

Taking a New Look with Intraoperative MRI

Low-grade brain tumors often masquerade as normal, healthy brain tissue. For many cancerous lesions, it can be nearly impossible to tell the difference during resections. Such mimicry can leave patients open to the danger of either removing too much tissue and harming healthy brain, or not being aggressive enough and increasing the risk of recurrence.

Over the years, neurosurgeons such as **Jon Weingart** have had an increasingly larger toolbox to distinguish normal from cancerous tissue during surgery. For example, he and other Johns Hopkins neurosurgeons use intraoperative navigation—a type of "GPS for the brain" that uses MRI images taken before surgery as its map. Because tumor tissue has a different signature on MRI, it allows surgeons to use these images as a guide to differentiate between diseased and healthy tissue during surgery.

However, Weingart says, this technology has a critical flaw: "The brain floats in water," he points out, "so there is some shifting and changing of things between when we take preoperative MRIs and when we're performing surgery."

Because even minor differences can make a statistically significant difference in patients' outcomes, he adds, it's important to remove just the right amount of tissue. That's the reason why Johns Hopkins included intraoperative MRI as part of the Sheikh Zayed Tower, one of The Johns Hopkins Hospital's new clinical buildings that opened last year.

Incorporating intraoperative MRI into the neurosurgery operating room suites required some special architectural planning, Weingart says. The imaging apparatus, which is shared between two operating rooms, hangs on a track suspended from the ceiling. Both rooms are shielded, just like rooms for regular MRIs.

Using the machine also requires planning during surgery. Patients must be encased in specially designed cocoons when they enter the tunnel to keep the field sterile, Weingart explains. Also, surgical instruments are carefully counted before a scan, since metal objects are attracted to the MRI's powerful magnet.

So far, the team has used the intraoperative MRI in more than 60 cases. In about 40 percent of those cases, surgeons ended up removing more tissue after patients received an intraoperative scan.

"That's very significant," Weingart says. "In nearly half of these cases, the intraoperative MRI allowed us to make a decision that could improve these patients' outcomes."

Weingart says that with each use of the technology, the team is gathering data to accurately measure the differences in patient outcomes compared to surgeries before intraoperative MRI was in place.

"Eventually, with enough data," he says, "intraoperative MRI could become the standard of care." ■

Information: 410-955-6406

continued from page 3

Though Leigh says more research is needed before this software enhancement can be widely implemented, he and his colleagues recently published proof of the concept in the journal *PLOS ONE*. Their findings show that the software identified varying levels of damage in nine stroke patients already known to have suffered a blood-brain barrier insult. The researchers are now examining results from a larger patient group to better define the meaning of these variations and how physicans can use this information to choose the best treatment.

"It's a personalization of medicine," Leigh says. "Rather than lumping everyone together, we can figure out—on a case-by-case basis—who should and who shouldn't get which treatment. In the long run, we can increase the number of patients we can help and decrease the number who have complications." ■

Information: 410-955-2228

Johns Hopkins CareLink

Johns Hopkins Medicine is pleased to introduce **Johns Hopkins CareLink**, a free Web-based portal that enables you to have real-time access to your patients' electronic medical records, lab results and imaging reports; provides CareLink in-box notification of your patients' outpatient visits and hospital admissions and discharges; and also enables you to send/receive secure messages with Johns Hopkins providers and order consults with Johns Hopkins specialists.

Enroll starting May 13, 2013, and begin accessing your patients' information on July 1, 2013. For more information on Johns Hopkins CareLink and enrollment instructions, please visit www.hopkinsmedicine.org/carelink. Enrollment is quick and easy. Once you have enrolled, you and your office colleagues can take brief online training and receive technical support by calling 855-284-5465.

NeuroLogic

Johns Hopkins Medicine
901 S. Bond Street/Suite 550
Baltimore, Maryland 21231

This newsletter is published for the Departments of Neurology and Neurosurgery by Johns Hopkins Medicine Marketing and Communications.

Departments of Neurology and Neurosurgery
Justin McArthur, *Director of Neurology*
Henry Brem, *Harvey Cushing Professor and Director of Neurosurgery*

Marketing and Communications
Dalal Haldeman, Ph.D., M.B.A., *vice president*
Christen Brownlee, *managing editor, writer*
Lori Kirkpatrick, *designer*
Keith Weller, *photographer*

With questions or comments, contact:
mayd@jhmi.edu or 410-955-2902

JOHNS HOPKINS MEDICINE

www.hopkinsmedicine.org/neuro

Non-Profit Org
U.S. Postage
PAID
Permit No. 5415
Baltimore, MD

NeuroLogic

NEWS FOR PHYSICIANS FROM THE DEPARTMENTS OF NEUROLOGY AND NEUROSURGERY

SPRING 2013

Inside

JOHNS HOPKINS MEDICINE